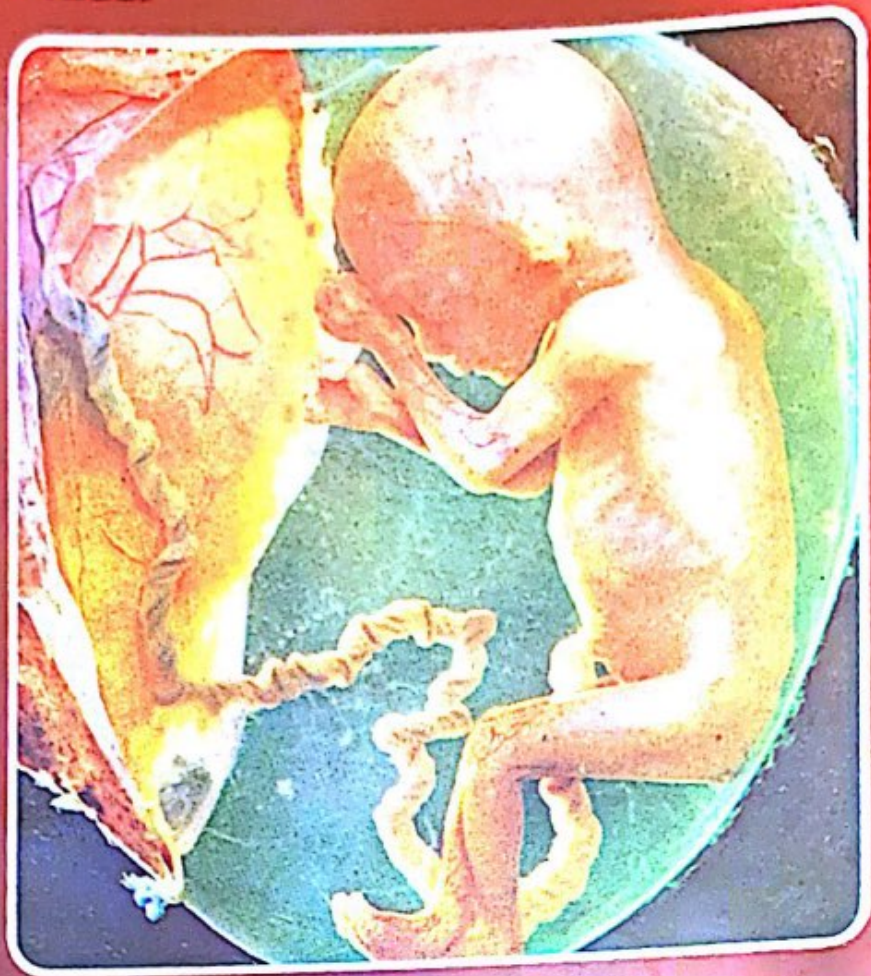


Dr. Mohammed Ali Albar



Human Development

**As Revealed in the Holy Quran
and Hadith**

**(the Creation of Man between
Medicine and the Quran)**

Saudi Publishing & Distributing House

All Rights Reserved
5th Edition
2013

Human Development As Revealed in the Holy Quran and Hadith

**(The Creation of Man between
Medicine and the Quran)**

Dr Mohammed Ali Albar

(M.R.C.P., D.M., M.B.B.Ch)
Consultant of Islamic Medicine
King Fahad Medical Research Center
King Abdul Aziz University
Jeddah

SAUDI PUBLISHING & DISTRIBUTING HOUSE

All Rights Reserved
5th Edition
2002



Saudi Publishing
& Distributing House

JEDDAH

Administration & Magazines:

Telephones: 6293988-6294039-6294278

Fax: 6294290

P.O.Box: 2043 Jeddah 21451

Cable: NASHER DAR.

DAMMAM

Telephone: 8347769

Fax: 8335520

P.O.Box: 899 Dammam 31421

Libraries: Dhahran Street. Tel: 8223515

King Saoud Street, Al-Hayat Plaza Center.

Tel: 8327452

RIYADH Branch:

P.O.Box: 2999 Riyadh 11461

Telephones: 4647894 - 4645767

© Saudi Publishing & Distributing House, 1415H

فهرسة مكتبة الملك فهد الوطنية

Albar, Mohammed Ali

Human Development

150 Pages, 14x20cm

ردمك 1-9960-26-001

الإنسان في القرآن - 3 القرآن والطب - 2 الخلق - 1

ديوي 229,461

رقم الايداع: 15/0460

ردمك 1-9960-26-001

بِسْمِ اللَّهِ الرَّحْمَنِ الرَّحِيمِ

قَالَ تَحَارَىٰ وَأَعَدَّ عَلِيمًا الْإِنْسَانَ مِنْ عَلَاقَةٍ مِنْ مَلَأْنِ ثُمَّ مَدَدْنَا نُطْفَةً فِي قَرَارٍ مَكِينٍ ثُمَّ حَقَّقْنَا النُّطْفَةَ عَلَمَةً تَلَمُّهُنَّ أَعْيُنُ الْمَلَائِكَةِ الْمُحْفَظَةِ ثُمَّ لَقَّيْنَاهَا أَهْلَ عِضْمَانٍ لَهَا ثُمَّ أَمْسَكْنَاهَا بِعِلْقٍ أَمْرٍ مَدْرُودٍ ثُمَّ لَقَّيْنَاهُ لِسَانَ الطَّلَقِ

CONTENTS

	Page
Preface	9
The Embryological Terms used in the Holy Quran and Hadith	11
Reproduction	13
The Male Reproductive System	17
The Female Reproductive System	29
Meiosis or Reduction Division and its Functions	41
Fertilization	45
A brief look into the History of Embryology	51
The Nutfah	57
The Alakah	63
The Modgha	71
Bone and Flesh Formation	79
The Sex of the Embryo	87
Giving the Shape and Form	95
Development of the Ears	107
Development of the Eyes	115
Three Veils of Darkness	123
When the Soul is inspired?	135
References	147

بسم الله الرحمن الرحيم

قال تعالى : « ولقد خلقنا الانسان من سلاله من طين . ثم جعلناه نطفة في قرار مكين ثم خلقنا النطفة علقه فخلقنا العلقه مضغه فخلقنا المضغه عظاما فكسونا العظام لحما ثم أنشأناه خلقا آخر فتبارك الله أحسن الخالقين » .

Sura 23/12-14 المؤمنون ١٢-١٤

“We created man from the quintessence of mud. Thereafter, We cause him to remain as a drop of sperm in a firm lodging (i.e. the womb). Thereafter We fashioned the sperm into something that clings (Alakah), which We fashioned into a chewed lump (Modgha). The chewed lump is fashioned into bones which are then covered with flesh. Then We nurse him unto another act of creation. Blessed is God, the best of artisans”.

وقال تعالى :

« مالكم لا ترجون لله وقارا وقد خلقكم أطوارا » .

نوح ١٣-١٤

Sura 71/Verse 13-14

“What is amiss with you that you cannot look forward to God’s Majesty. He created every one of you in successive stages”.

وقال تعالى :

« فلينظر الانسان مم خلق . خلق من ماء دافق يخرج من بين الصلب

والترائب » .

الطارق ٥-٨

Sura 85/5-8

“Let man then observe out of what he has been created; he has been created out of gushing water (ejaculated fluid), which comes out from between the vertebral column and the ribs”.

PREFACE

Four years have elapsed since this book was first published in Arabic under the title "The Creation of Man between Medicine and the Quran," and Al Hamdulillah; it received much appreciation from many a circle and the public. Many a friend has asked me to translate it into English.

I hesitated a lot, as I felt the book as such is addressing Muslims who have some understanding of basic sciences especially biology, as well as some understanding of Islamic teachings present in the Holy Quran, Hadith (Traditions) of the Prophet Mohammad (peace be upon him) and their multiple explanations by the ulema (the learned people of Islamic religion).

When the 8th Saudi Medical Conference was held in Riyadh (30th Oct — 2nd Nov. 1983), one of its main subjects was 'Corroboration of scientific truths in the Holy Quran and Hadith.'

As the revelations of God, the Holy Quran and Hadith of the Prophet (peace be upon him) contained many facts and conjectures concerning medical and scientific data that were never known by humans except recently. Some of these data were only known in the second half of the twentieth century.

Many renowned names both from the Islamic countries and the West participated in this subject.

Professor Keith Moore, Professor Simpson, Professor Mohammad Taher, Professor Marshall Johnson, Professor Persaud, Professor Salman, and Sheikh Abdul Majid Zindani, to name a few, all participated with many shrewd and enlightening papers.

The author of this book presented three papers, one of which was under the title "Embryological data in the Holy Quran and Hadith."

The time seemed ripe enough to indulge in the difficult task of re-writing my Arabic book "The Creation of Man between Medicine and the Quran" whose subject is the development of man in the womb, as exposed in the Holy Quran and Hadith corroborated with the science of embryology as it is known today.

Some introductory chapters, explaining the reproduction, the male and female genital systems, were felt necessary before embarking on the corroboration study.

Many illustrations were borrowed from other texts, in order to make it easy for the layman who is interested in the subject, to follow it without great difficulty.

It is however felt that medical students in Islamic countries may benefit from it as it corroborates their curriculum in Embryology with the Quranic verses, and sayings of the Prophet Mohammad (peace be upon him).

Those in the medical and paramedical professions, especially Muslims, may find it useful if they have the interest in the subject. They can skip the introductory chapters and proceed to chapter 7 "A brief look into the History of Embryology," P59.

This does not mean that those outside the profession, may not make use of it. In fact, it is written for all those who show interest in the subject whether they are attached to the medical profession or not.

It is intended to expose the miracles of the Holy Quran and the Hadith of the Prophet Mohammad (peace be upon him) in a limited field of science, viz: embryology.

The study of the scriptures (Quran and Hadith) in the light of the scientific knowledge of the twentieth century, gives a better understanding of these scriptures.

The data concerning other branches of medical knowledge will need separate books.

Lastly, I must express my thanks and gratitude to Professor Mohammed Taher, Professor of Anatomy and Embryology, King Abdulaziz University, for his diligent and consistent help in reading the manuscript and commenting upon it. I am also indebted to Mr Zariief who typed the manuscript, and the publishers for their keen interest and support.

Dr Mohammed Ali ALBAR
Jeddah
25th Jumada Al Akhira 1404H
27 March 1984

The Embryological Terms Used In The Holy Quran And Hadith

The embryological terms as presented in the Holy Quran substantiated by the Prophet Mohammad's (peace be upon him) sayings will be explained here.

It is quite revealing that we find that the Holy Quran, has clearly explained the stages of formation of the human embryo, in a way that was never known before the 19th and 20th centuries.

The stages of human development in the "Womb" as expressed in the Holy Quran fall into the following:-

1. NUTFAH

Literally meaning "a drop of fluid". In the Quran it is used in three different but interwoven connotations, viz:

- i. Male Nutfah
- ii. The female Nutfah (clearly explained in the Hadith)
- iii. The mingled Nutfah from both male and female Nutfahs intermingled and completely mixed in each other.. expressed in the Quran as "Nutfatul Amshaq".

2. THE ALAKAH

Literally meaning "Something that clings and adheres" to the womb, viz: clearly describing the implantation stage.

3. THE MODGHA

Literally meaning "a piece of flesh that has been chewed". The Quran depicts this stage as if it was a piece of flesh or food that has been chewed and the indentation marks of the teeth are clearly shown on this "Modgha".

This "Modgha" fits well in the "Somite stage" in the science of Embryology.

The Modgha is further divided in the Holy Quran into:

- i. Modgha Mokhalaga
- ii. Modgha non-Mokhalaga

The exegesis of Mokhalaga and non-Mokhalaga point to the

- a. Formation of organs at this stage (Mokhalaga)
- b. Abortions occurring at this stage (non-Mokhalaga)
- c. Differentiations: which starts in non-Mokhalaga and continues through the whole life.

In Embryology this is the stage of "Organogenesis" and the zenith of differentiation of the cells.

The timing of this stage is prophesied by the "Hadith" of the Prophet Mohammad (peace be upon him) which is stated at 40-45 days after fertilization.

4. FORMATION OF BONE AND FLESH FROM "MODGHA".

The Quran clearly states that the "Modgha" is transformed into bone and the bones are covered by flesh (muscles).

This concept is clearly found in embryology of today where the somite differentiates into:-

- a. Sclerotome from which the skeletal system is formed.
- b. Myotome from which the muscular system is formed.

The skeletal system precedes the muscular system in appearance. The "bone" once formed is enwrapped by flesh (muscle).

5. The concept of the human embryo being formed in stages from the simple to the more complex is a completely new development in human knowledge, which was first put down by Wolff in 1839.

The Holy Quran, the Hadith and the exegesis of those who made Tafsir since the time of Ibn Abbas, the Prophet's cousin, all outline this concept — 13 centuries before the subject was scientifically investigated.

Reproduction

All living creatures have a limited life span. The mechanism by which God had endowed these creatures to remain on earth, is by reproduction, in which new generations of the same species are produced.

The presence of the two sexes may be occult or manifest, they may be separate in two individuals or combined in one.

In most multicellular organisms, the sexes are separate in two distinct individuals, the male and the female.

The sex cells are called gametes; the male sex cells are the Spermatozoa; the female sex cell is the ovum (egg). The organs which produce the gametes are called the gonads. The male gonads are the testes, the female gonads are the ovaries. The unified cell resulting from the union of the male Spermatozoon and the female ovum is called the zygote. The process of union is called fertilization. The zygote contains half its content from the mother i.e. the ovum, and the other half from the father i.e. the Spermatozoon (sperm). Thus the new individual inherits many of its characteristics from both its parents and their ancestors. There is an interplay between the hereditary factors and the environmental factors, which complicates the matter further. In itself the hereditary factors are not simple. Some of the characteristics are dominant and some are recessive. In dominant characteristics only one gene either from the father or mother, if present, is sufficient to show in the new born; while in recessive characteristics, only when genes from both the mother and father are donated to the offspring that it may appear or become expressed.

These laws of heredity were first described by Mendel (1), an Austrian monk, in 1866 in his article "Experiments with Plant Hybrids."

They were completely ignored until Morgan (2) in 1912 discovered the chromosomes and their role in heredity (28 years after the death of Mendel).

The basic laws of Mendel were the corner-stone on which the Science of Genetics was later on built.

Things were found much more complicated than the simple laws of Mendel predicted. However they remain the basic laws to understand genetics.

It is quite astonishing to find the Quran and sayings (Hadith) of the Prophet Mohammad have discussed the subject of reproduction and Genetics.

In this book we will try to correlate many of the Quranic verses and sayings of the Prophet Mohammad (Peace be upon him) with what we know in the light of modern science and medicine of the twentieth century.

Here we will mention a few of the verses that mention parity and reproduction.

ومن كل شيء خلقنا زوجين لعلكم تذكرون « آية ٤٩ الذاريات ٥١ »

Sura 51/Verse 49

"And of everything We have created pairs, that you consider thoughtfully."

ومن كل الثمرات جعل فيها زوجين اثنين « آية ٢ الرعد ١٣ »

Sura 13/3

"Of every kind of plant He created two sexes."

سبحان الذي خلق الأزواج كلها مما تنبت الأرض ومن انفسهم ومما لا يعلمون « ٢٦ يس ٢٦ »

Sura 36/36

"Glory to God Who created in pairs all things that the earth produces, and in human kind. And other things of which they have no knowledge."

وانه خلق الزوجين الذكر والانثى من نطفة اذا تمنى « آية ٤٥ النجم ٥٣ »

Sura 53/45

"And He created both male and female from a drop of liquid that has been ejaculated."

فجعل منه الزوجين الذكر والانثى « آية ٣٩ القيامة ٧٥ »

Sura 75/39

"And He out of that semen made both sexes the male and the female."

والذي خلق الأزواج كلها « آية ١٢ الزخرف ٤٣ »

Sura 43/12

“He created pairs in all things.”

والذي جعل لكم من أنفسكم أزواجا « آية ٧٢ النحل ١٦ »

Sura 16/72

“God has made for you mates (and companions) of your own nature.”

ومن آياته أن خلق لكم من أنفسكم أزواجا لتسكنوا إليها وجعل بينكم مودة
ورحمة ان في ذلك لآيات لقوم يتفكرون « آية ٢١ الروم ٣٠ »

Sura 30/21

“And among His signs, He created for you mates from among yourselves that you may dwell in tranquillity with them. And He put love and mercy between your hearts. Verily in that are signs for those who reflect.”

The above mentioned verses of the Quran speak of the astonishing fact in which everything is found in pairs down from the atom, where the negative electron is complemented by the positive proton, involving every living and non-living things. The male lives with the female, and gonads are in pairs. The chromosomes themselves are found in pairs. The spermatozoa are two types.

- a) those carrying the Y or male chromosome.
- b) those carrying the X or female chromosome.

The human being is formed by the union of both male gamete (sperm) and female gamete (ovum), forming a union-cell called zygote. The zygote is the Quranic “Nutfatulamshaq” which forms from the mingling and mixing of the male Nutfah and female Nutfah. This will be explained fully in the chapter on Nutfah.

The Prophet Mohammad tells a Jew that man is created from both the male Nutfah (sperm) and the female Nutfah (ovum).

He also speaks of the genetic factors and tells an Arab that once the Nutfah is inside the womb (Uterus) God brings forth its genetic relation with its ancestors up to Adam.⁽³⁾ He tells another Beduin Arab who com-

plained that his wife delivered a black boy while neither of the parents were black, that the boy could have inherited this colour from his ancestors.⁽⁴⁾

Many such extraordinary revelations are found in the Holy Quran and the Prophet Mohammad's (Peace be upon him) sayings (Hadith).

REFERENCES

- 1) Mendel, Encyclopedia Britannica Vol II/898-899, 15th Edition 1982
- 2) Leslie Arey, Developmental Anatomy, 7th Edition, P6
- 3) Ibn Jarir Al Tabari and Ibn Abi Hatim
- 4) Narrated by Al Bokhari, Muslim, Al Nisayi, Al Termzi, Ibn Maja, Abu Da'ood, Ahmed Ibn Hanbal and Al Dar Qotni.

The Male Reproductive System

FORMATION OF THE MALE GAMETE OR SPERM (Nutfah)

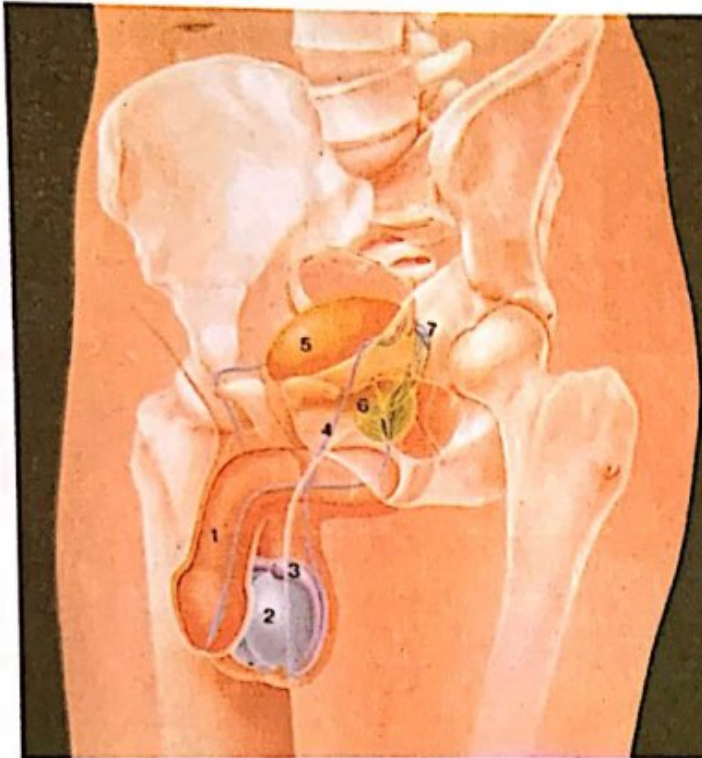


Fig. 1

- 1. Penis with erectile tissue*
- 2. Lt testicle*
- 3. Lt epididymis*
- 4. Lt spermatic cord*
- 5. Urinary bladder*
- 6. Prostate*
- 7. Seminal vesicle*

The male reproductive system is composed of the sex gland "the testes" which are two almond like glands lying outside the body in the Scrotum where the temperature is 2 degrees less than body temperature. The testes are under control of the pituitary gland situated in the base of the skull in the Sella turcica or the "Turkish saddle", as it resembles it in shape. The pituitary itself is controlled by the hypothalamus, a portion of the brain responsible for controlling all the autonomic nervous system and hormones of the body. At time of puberty (12 to 16 for boys) the hypothalamus stops secreting the inhibiting hormones to the pituitary. The pituitary then releases the gonadotrophic hormones which allows the growth and maturation of the testicles. The other parts of the reproductive system in the male are auxilliary. The secretions of the testicles are stored in a canal called epididymis and then passed into the spermatic

cord to the upper part of the urethra. The secretions of the seminal vesicles, the prostate and the Cowper's glands are added to the sperms.

They act as a nutrient and protective medium in which the sperms are activated, and nourished. The sperms swim actively in the semen. The semen is ejaculated through the Urethra by the erectile tissues of the penis and the contractions of the Pelvic and Perineal muscles of the body.

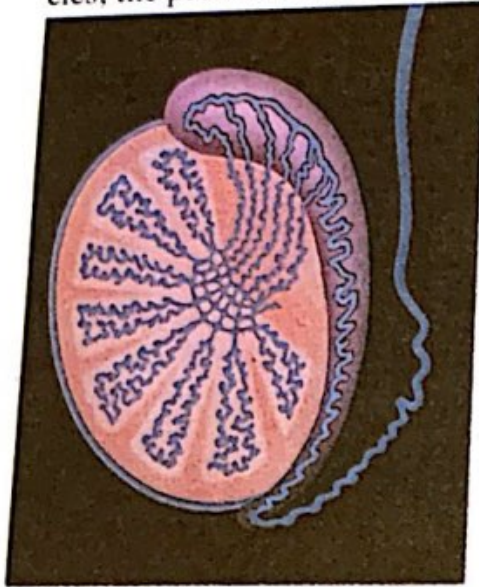


Fig. 2 Testicle, epididymis and spermatic cord

The Convoluted Tubules

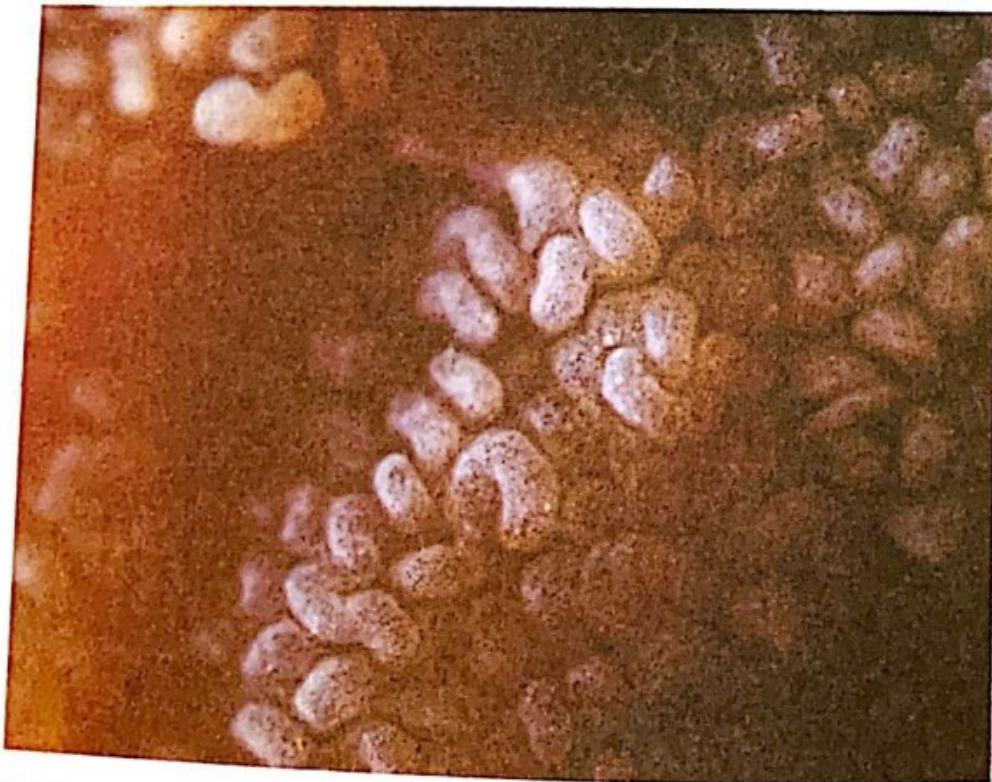


Fig 3. The convoluted tubules (Semeniferous tubules) where sperms are formed.

These are the tubules where the sperms "Male Nutfas" are made, under the effect of pituitary gonado-trophic hormones (F.S.H. and L.H.). There are about 1000 such tubules, each tubule is about $\frac{1}{2}$ a metre long the total length being half a kilometre, packed in a space of no more than 5 cms. These convoluted tubules are called Seminiferous tubules because they produce the semen. The rate of production is indeed very high: 100 million sperms daily, from the time of puberty (12-16) till the age of 60 or more. These tubules produce, not only sperms, but the sex hormone testosterone which is responsible for the secondary sex characteristics of the male e.g. beard, moustache, masculine build and sexual libido.

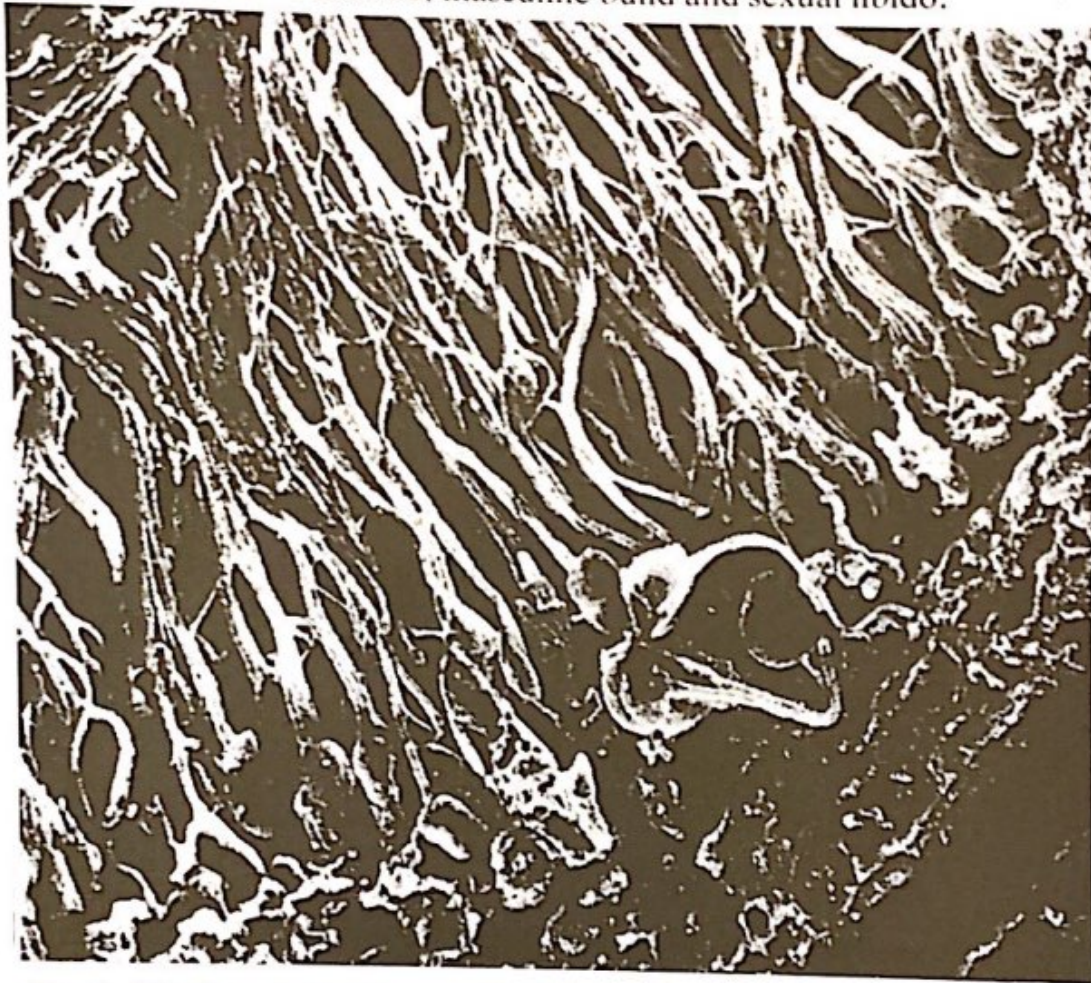


Fig. 4. This is a photo micrograph of a cross section in one of the convoluted seminiferous tubules shown in fig. 3. It is magnified a few thousand times by electron microscope. The sperms are formed in the wall of this tubule whereby the sex cell of the tubule divided twice ending in 4 cells. Each of the new cells contains half the number of chromosomes where the genetic material is stored. The cells grow and mature in three weeks time, when they acquire a big head containing the genetic material, a middle piece containing the fuel tank "mitochondria" and a whip-like tail by which it swims all the way to the female egg in the fallopian tubes.

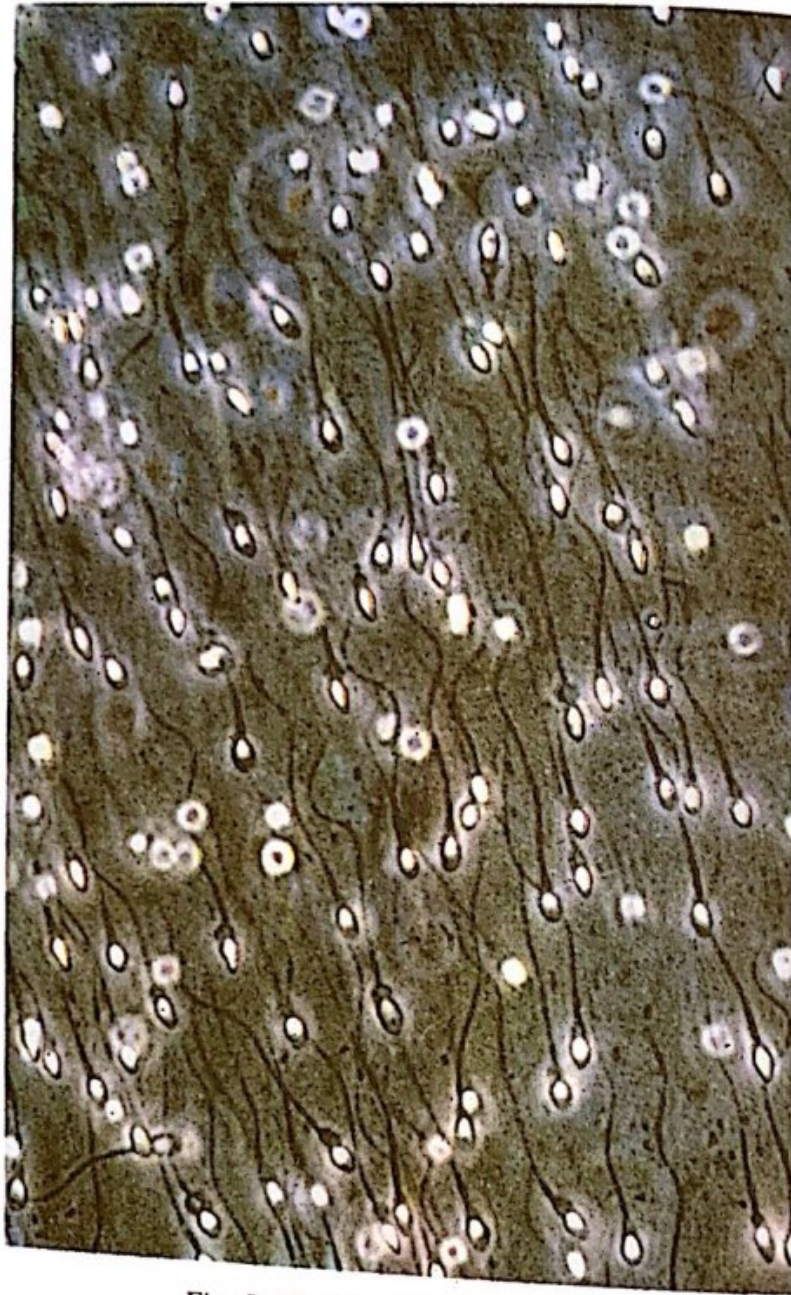


Fig. 5. The Nutfah of the Male

A small drop of semen magnified 450 times. The spermatozoa (the sperms), counting 200 to 300 million in each ejaculation, are small creatures with oval heads, which contain the genetic material from the father, the middle piece which provides energy for the fast swimming spermatozoa (mitochondria) and a long whipping tail which helps the sperms make their lengthy journey from the vagina to the fallopian tubes. The length of the head is no more than 6 microns while the whole length of the sperm and its tail averages 60 microns (1 micron = $1/1000$ mm).

The sperms are fast swimmers (2-3 mm/minute⁽¹⁾), and compared to their size they will beat the world record for 100 metres by half the time.

A drop of semen from which the human being is created. God says: "Was he (viz. man) not a mere sperm out of semen ejaculated. Thereafter he became a leech like clinging object, which He created into different organs, and gave its form and shape. And He out of that semen, made both sexes the male and the female. Is it not He then, able to bring the dead back to life." *Sura 75/37-40*

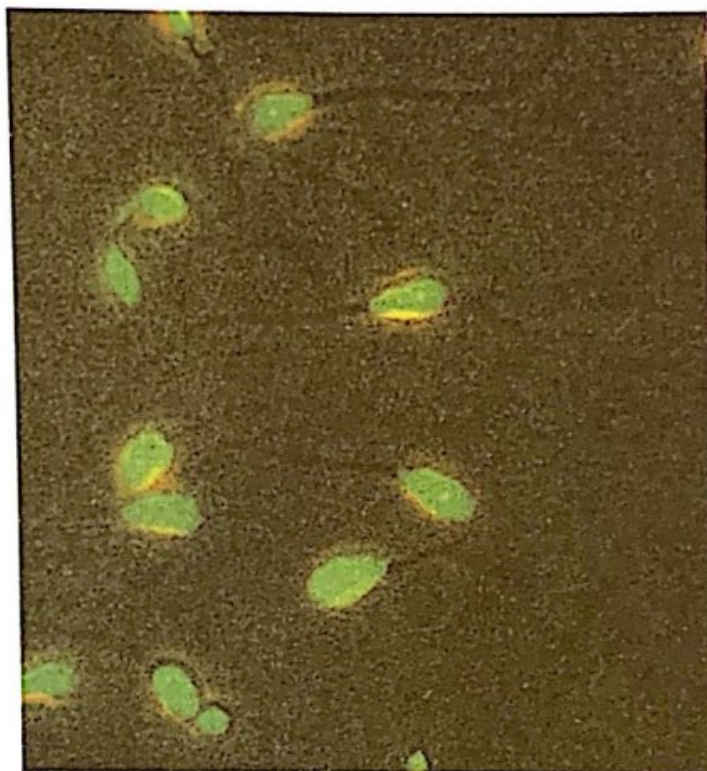


Fig. 6

In this photo there are two types of sperms:

- i) Sperms (male) containing Y Chromosome which shows as a bright dot in the middle of the head of the sperm*
- ii) Sperms (female): containing X Chromosome which do not show the bright spot.*

The above mentioned verse from Quran clearly points to this fact, "And He out of that semen made both sexes the male and the female." This was never known until the twentieth century. The Quran stated this fact 14 centuries ago.

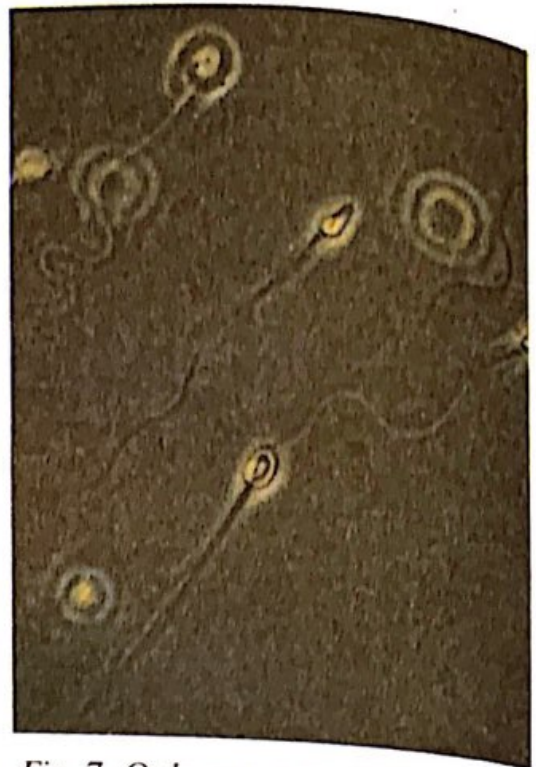
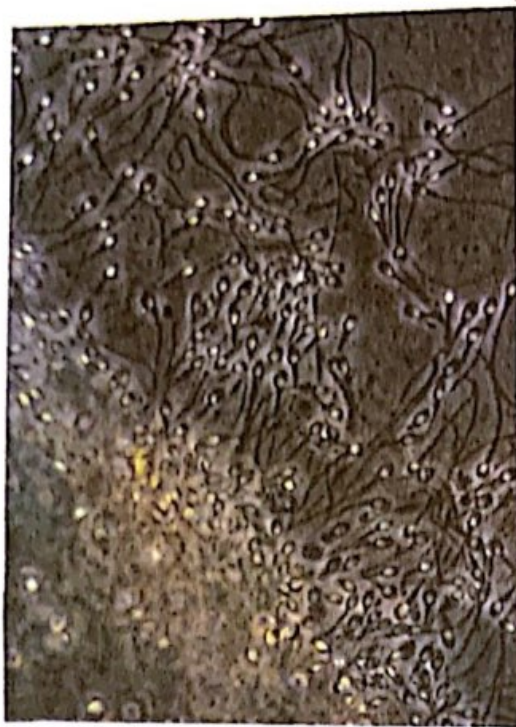
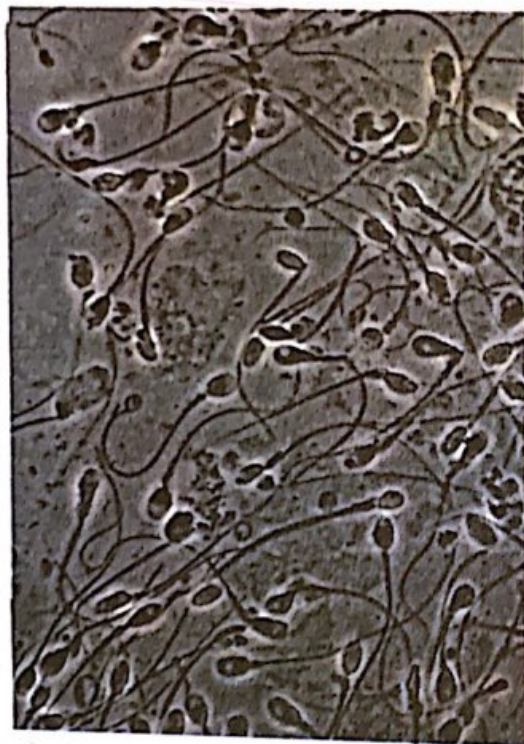


Fig. 7. Only one, out of 300 million sperms, fertilizes the ovum



Out of the hundreds of millions of sperms ejaculated in every sexual act, only one of these millions does occasionally succeed in fertilizing the female ovum (egg). In the photomicrographs (a-c) hundreds of sperms die at the cervix (neck) of the uterus (womb); only 400 sperms or so reach the ovum.

The sperms constitute $\frac{1}{2}$ to 1 per cent of the whole seminal fluid ejaculated by the male. Nevertheless it contains an average of 200-300 million sperms. Only one of these millions succeeds in fertilizing the ovum (egg) of the female. The testes secrete daily 100 million sperms.

On the other hand the ovary of the unborn female infant contains more than 400,000 eggs. The majority die even before the child is born. Only 30,000 eggs are found at the time of birth. By the time the girl reaches puberty many thousands of these eggs will die and become atretic. Only one egg matures monthly throughout the sexual life of the female i.e. no more than 400 eggs throughout the whole life span.

Nevertheless, only few eggs are fertilized, and even then few of these fertilized eggs are allowed to grow into babies. The majority of the fertilized eggs are aborted, even before the mother knows that she is pregnant.

These astonishing facts were only known very recently (in the seventies of the twentieth century). The Holy Quran 14 centuries ago says:



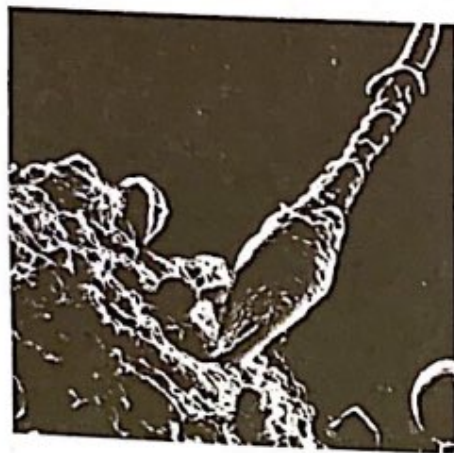
Fig 8
Photo of a sperm in the long journey with its head like a rocket, its fuel tank in the neck, and its propellant whip like tail. Millions of sperms die before few reach successfully the ovum.

“God made man’s progeny from a quintessence of despised liquid.” Sura 32/8. In another Sura (75/37) He says: “Was he (i.e. man) not a mere sperm out of semen that has been ejaculated.”

The Prophet Mohammad (Peace be upon him) said: “Not from the whole fluid (ejaculated), man is created, but only from a small portion of it.”

When asked by a Jew from what thing man is created, He answered: “O Jew from both male Nutfah (sperm) and female Nutfah (egg) man is created.”

The characteristics of the female ovum are completely different from those of the male sperm. The ovum is a beautiful, receptive moon-like cell which moves very little and resembles a queen wearing her radiating crown (Corona radiata) while the male sperm is small, active, agile, resembles a rocket, faces dangers and is aggressive, which either reaches its goal or dies. In short the sperm is positive and dominating while the female ovum is negative and receptive.



Figs. 9 & 10

These two pictures taken by an electron microscope illustrate the passivity and receptivity of the (female) ovum, and the dominant aggressive behaviour of the (male) sperm, where it reaches the surface of the ovum like a rocket reaching the surface of the moon. It penetrates the wall and releases its well kept chromosomes into the female ovum, whereby they unite forming the fertilized ovum or zygote. The Quran has already explained this astonishing phenomenon 14 centuries ago.

Sura 76/Verse 2 reads as follows:

“Verily, We have created man from a drop of mingled liquids of both male and the female.” The so called Nutfatul amshaq is the resultant of

the mixing and mingling of the male Nutfah (sperm) and the female Nutfah (ovum).

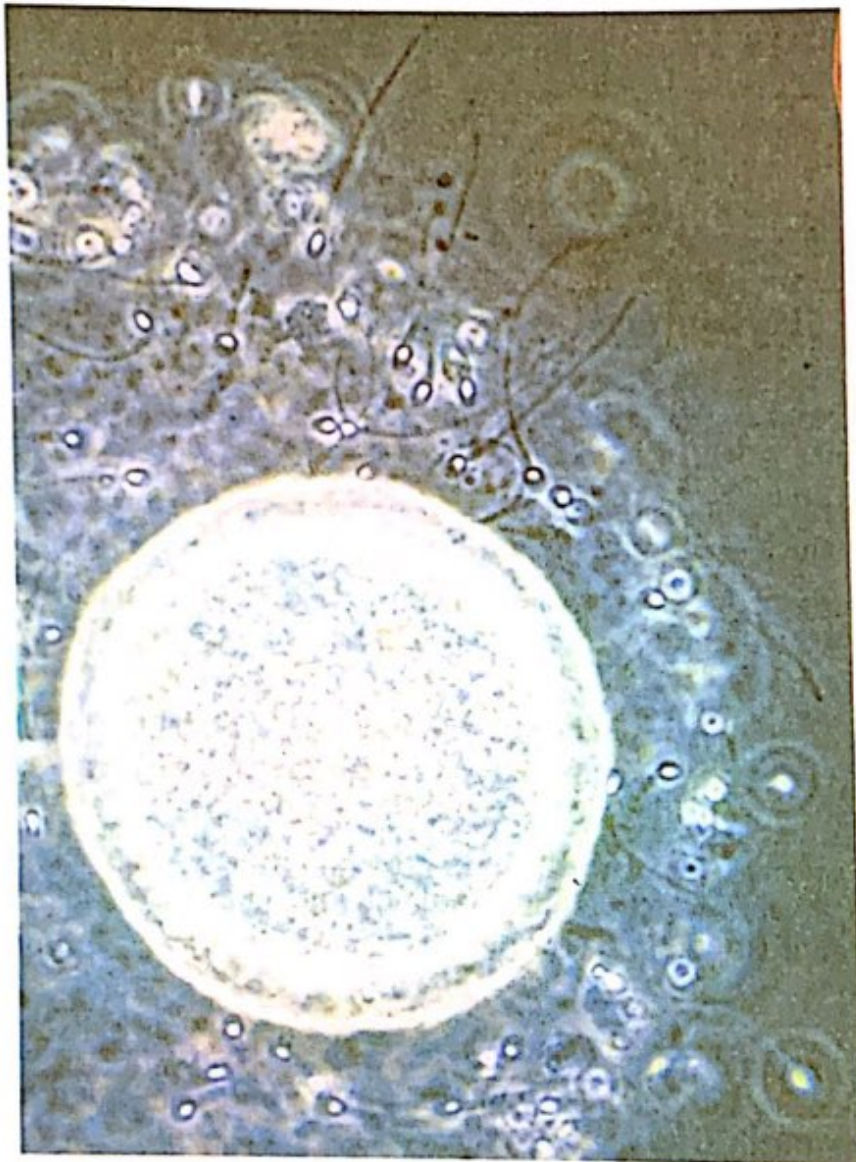


Fig 11
The ovum surrounded by hundreds of sperms.

Only a few of the hundreds of millions of sperms do reach the ovum after a very dangerous and hazardous journey. The ovum (egg) looks like a full moon surrounded by the corona radiata (the radiating crown). It moves very little in contrast to the active and agile sperms. Its size is 120 microns (0.12 mm), i.e. it is the biggest cell in the human body, while the head of the sperm measures only 5 to 6 microns.

The accessory or secondary sex organs

The testes are the primary male sex organs. The tubes which convey the seminal fluid secreted by the testes form the major part of the accessory sex organs. The convoluted "Seminiferous tubules" of the testes convey the semen to the epididymis via twenty or so, small tubules called efferent ductules. The epididymis, which lies at the posterior surface of the testes, is a coiled duct of 6 metres long that lie in a 6 cm space. Here the sperms rest for three weeks to get mature, and acquire the ability to swim. The sperms become fast runners indeed. Compared size to size, they will break the 100 metre world record by half the time.

The sperms are then delivered to the vas deferens which runs from the lower end of the epididymis into the inside of the abdomen through the inguinal canal. Its length is about 40cm.

It ends by joining the duct of the seminal vesicle to form the ejaculatory duct which opens into the urethra.

The seminal vesicle is 5 cm in length, situated at the back side of the bladder, which secrete a nourishing fluid to the sperms. There are two seminal vesicles.

The Prostate is a spongy gland, the size of a golf ball, which secretes fluid, containing nourishing material for the sperms, which pass through thirty small tiny openings into the ejaculatory duct.

The sperms constitute only one per cent of the semen. The rest of it is made up by the secretions of the Prostate, the seminal vesicles and small glands around the urethra (Littre's gland and Cowper's).

The urethra is a long duct which conveys: [1] the urine from the urinary bladder to the outside during micturition, [2] the semen from the ejaculatory duct to the vagina during coitus.

It is divided into three parts: [1] Prostatic part [2] the membranous part which is the narrowest part of the urethra — It is continuous with the prostatic part of urethra. Its length is only 1.5 mm. [3] the anterior urethra: 15 cm long, traverses the penis to the external meatus (opening). The penis is an erectile tissue which stiffens during sexual arousal to allow penetration into the vagina, and conveys the seminal fluid.

At the end of the Penis is the glans which is covered by a thick skin called Prepuce. The under surface of the prepuce secretes a thick fatty substance "Sebum" which needs to be cleaned frequently.

The prepuce is removed during circumcision which is practiced by Muslims and Jews.

The Prophet (peace be upon him) in many of his teachings (Hadiths) narrated by authentic books of Hadith, AlBokhari, Muslim, Ahmed Ibn Hambal and others, has ordered Muslims to circumcise their children and also those who embrace Islam.

It became known recently that *circumcision of boys decreases the incidence of*: [1] Phimosis: narrowing of the urethral meatus due to adhesion of the prepuce to the glans penis; [2] cancer of the penis; [3] cancer of the cervix in the female partner.

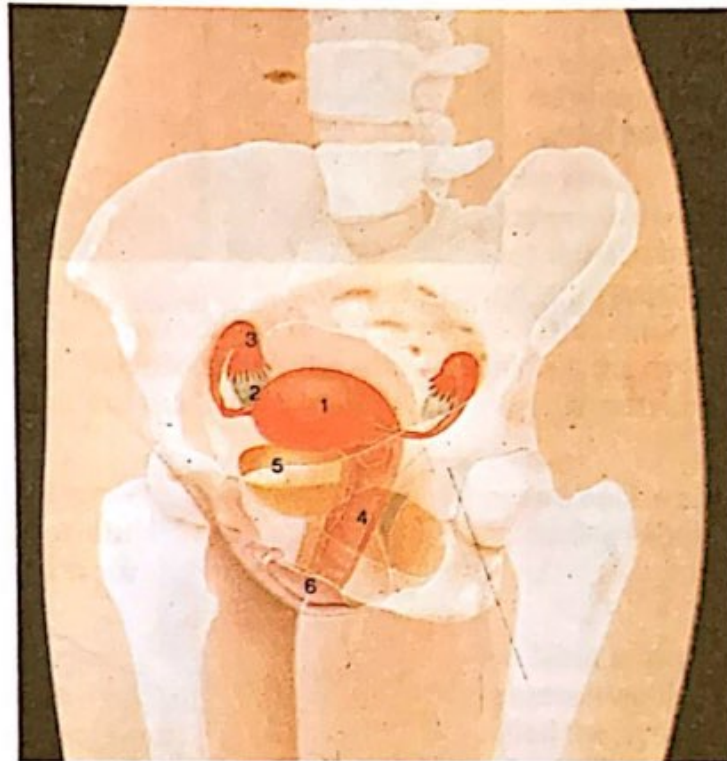
Arya and others in "Tropical Venereology" says: Circumcision, in the case of men, although not affecting the incidence of gono or syphilis, may help prevent some cases of balanitis, genital herpes, genital warts and chancroid.

Circumcision seems, therefore, to play a role in protection against serious diseases.

REFERENCES

1. Leslie Arey: Development Anatomy, 7th Edition P53
2. Arya, Bennett, Osoba: Tropical Venereology, Churchill Livingstone 1980 206

The Female Reproduction System



1. Uterus (Womb)
2. Ovary
3. Fallopian tube
4. Vagina
5. Urinary bladder
6. Labia majora

Fig. 12 Showing the genital organs of the female inside the Pelvis.

The vagina is elastic and hence the front (anterior) and back (posterior) walls are in contact with each other except during coitus or delivery of the baby (parturition).

The female pelvis is broader and shallower than that of the male, and more open at the bottom. Its bones are thinner and the indentation marks on its surface are less than those of the male. The differences between male and female are so dramatic both in the physical and psychological state that it seems contrary to their nature to give them the same role in life.

Sura 3/36 of the Holy Quran says:
 "And nowise is the male like the female".

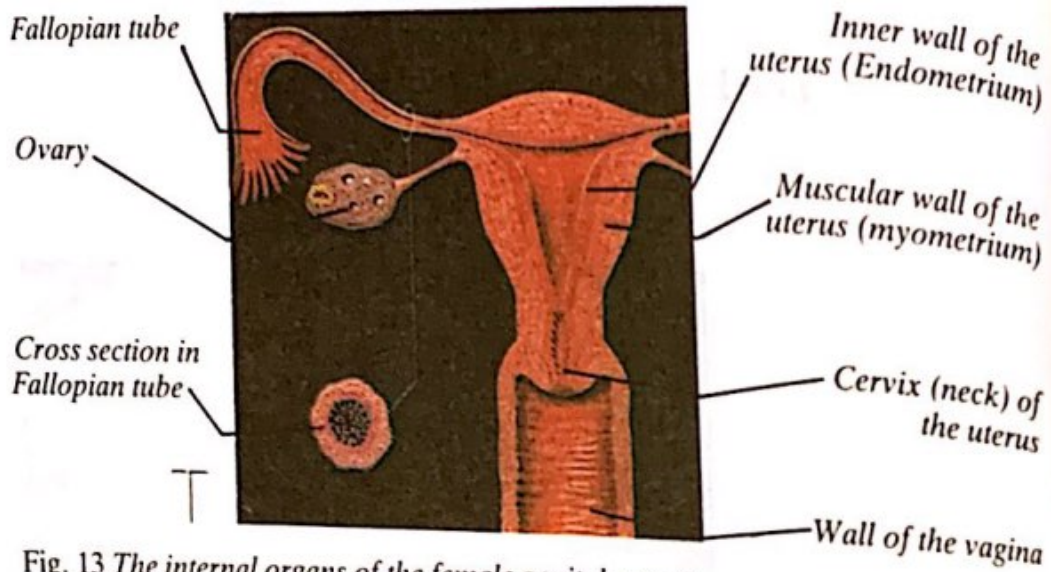


Fig. 13 The internal organs of the female genital system.

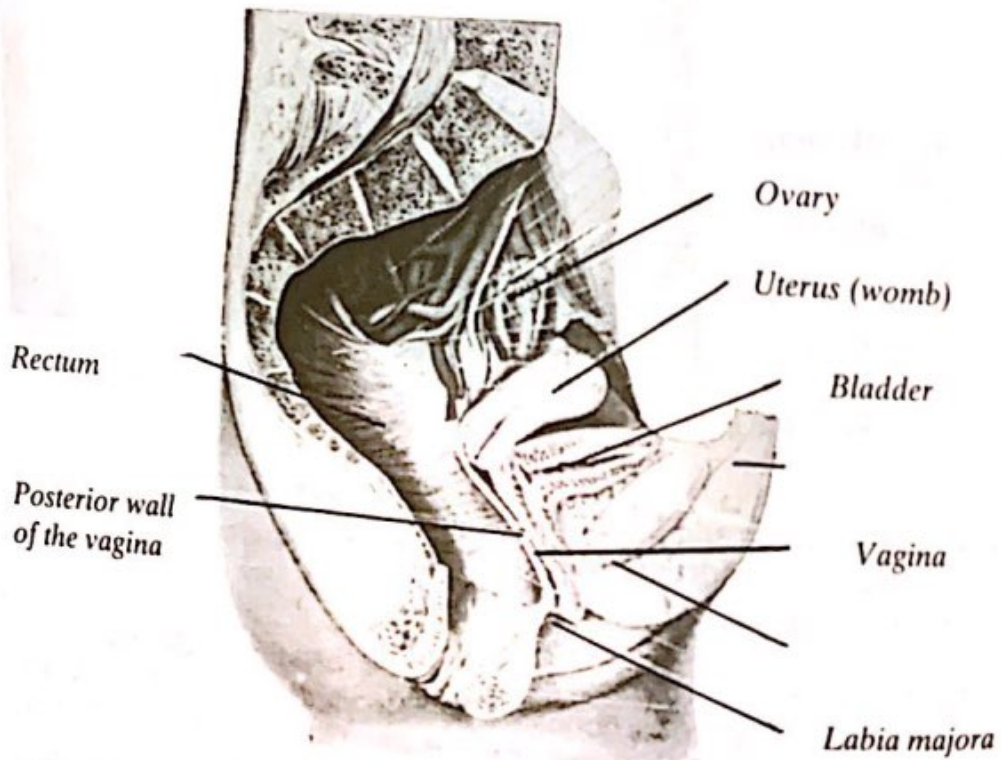


Fig. 14 Longitudinal section showing the female reproductive system. The relation of the uterus (womb) to the pelvic organs are illustrated.

The female Reproductive System is made up of internal and external organs. The internal organs which are important are:

[1] *The ovaries*: There are two almond like ovaries, one in each side of the pelvis. They are the gonads or sexual glands of the female. Only one egg (ovum) is produced monthly from one or the other ovary from the time of puberty (12 — 16) to the age of menopause (45 — 55).

[2] *Uterus or womb*: A pear-like organ in which the human seed (the fertilized ovum) grows into a baby which is born at the time of delivery.

[3] *Fallopian tubes* (uterine tubes) are two thin tubes which arise from the corner ends of the womb (uterus), being one on each side and connecting the uterus with the ovary. The end of the tube is funnel-shaped and is fimbriated. It is not directly connected to the ovary. The free end of the funnel-like tube sways around the ovary and picks up the released ovum (egg) from the ovary. It carries it to its outer third, where fertilization (union) with the male sperm occurs. Later on it pushes the fertilized ovum by muscular contractions down to uterus. The inside of the tube is covered with hair like processes, the cilia, which push the ovum towards the uterus. If they are destroyed by infection, e.g. gonorrhoea, sterility ensues.

[4] *The vagina*: is a narrow elastic tube where the front and back walls are kept in contact except during coitus (sexual act) or during labour when it allows the baby to come down to the new world.

The external genital organs: two labia majora and two labia minora. The opening between the two labia minora is called interoitus. It is covered by a thin membrane (sometimes thick) which is called the hymen. This membrane is usually ruptured during the first sexual act. Occasionally it is so elastic that coitus could be performed without rupturing it. In such cases it is only ruptured during delivery.

The hymen is usually perforated and is crescentic in shape allowing the menstruation. Sometimes it is completely closing the interoitus and does not allow the menstrual blood to flow.

Such cases require incision by the gynaecologist to allow the menstrual blood to flow out.

The clitoris is a very small erectile organ resembling the male penis in its structure, but differing in being not penetrated by the urethra.

The urethra opens separately above the interoitus. The ovaries and the uterus will be discussed in more detail (in a simplified language).

The Ovaries

The paired almond-like ovaries situated in the true pelvis, are the primary female sex organs. They produce monthly one sex cell (the gamete or the ovum or the egg) on alternate bases i.e. one ovary produces an ovum one month and the other ovary the next month. Occasionally they produce their eggs simultaneously. If both eggs are fertilized, unidentical twin pregnancy occurs.

The ovary is not only responsible for producing the eggs (ova), but they are also responsible for producing the female sex hormones (oestrogen and progesterone) which control the secondary sexual characteristics of the female and cause the cyclic changes of mature sexual life, and of pregnancy.

These manifest and subtle changes that endow the pubescent girl with femininity, and strike the hundred and one differences between her and her brother, are mainly due to the effects of the female sex hormones produced by the ovaries.

The growth of the breasts (mammary glands), the distribution of pubic and axillary hair, the feminine voice, the distribution of fat in the body in a special way that make the abdomen and buttocks fat depots, the characteristic shape of the female bones especially the pelvic bones, and a lot of other subtle and manifest characteristics including the sex libido, and the passivity and shyness of the female, are all effected by the female sex hormones produced by the ovary.

While the female is still in her mother's womb at about the 6th or 7th week it becomes possible to differentiate between male and female sex glands (gonads) i.e. testes or ovaries.

Each ovary then contains about 6 million primary sex cells. By the time of birth the majority of these sex cells are already dead. Only 400,000 primary sex cells are found at the time of birth. By the age of (12-16) i.e. time of puberty they are already reduced to 50,000.

As one ovum matures every month and is extruded from the ovary to the Fallopian tube, the total number of ova (eggs) produced in the whole life-time of the female is no more than 400.

In contrast to this, the male produces 100 million sperms daily i.e. 3 billion sperms for each ovum produced by the female.

The ovary is nevertheless a more complex endocrine gland than the testes, and undergoes cyclic changes, while the male sex hormones are essentially uniform and continuous. The ovarian hormones include:

i] *Oestrogens*: (Oestrus: heat). The oestrogens are hormones causing the sexual heat of the female, when the female becomes receptive to the male. Her whole body is made ready to receive the male internally and externally. She becomes more appealing to the male. Internally the ovary is ready to shed out the ovum. The uterus grows in size, its blood supply becomes more abundant and its glands elongate.

ii] *Progesterone* is the hormone of pregnancy. It is mainly produced after the shedding of the ovum (egg) from the ovary. The uterus undergoes marked changes in preparation for the implantation of the fertilized ovum in the uterus (womb). The breasts are also prepared for the pregnancy, by forming the milk glands inside the mammary glands (breasts). The whole body starts to store the important substances that would be required during pregnancy.

iii] *the androgens*: Small amounts of male hormones are also produced by the ovary to balance the excessive femininity caused by the oestrogens. It also participates in increasing the sex libido.

iv] *relaxin*: this hormone is only produced in pregnancy, especially late in pregnancy, to prepare for the delivery of the baby, by relaxing the ligaments that hold the pelvic bones tightly.

The uterus or womb: is a pear shaped organ situated in the middle of the true pelvis; from its lateral end come the uterine tubes (Fallopian tubes). It is suspended by many ligaments. Though the uterus is fixed by these ligaments, it has a great degree of mobility. During pregnancy its size grows until it fills the whole abdomen. The capacity of the inside of the uterus is 2ml, at the end of pregnancy (at term), its capacity reaches 7000ml.

The uterus weighs 50gm in non-pregnant ladies and by the end of pregnancy, it weighs one whole kilogram.

The uterus or womb is therefore capable of changing its size, shape and weight enormously.

Similarly, the inside of the uterus shows cyclical changes.

The uterus is made up of three layers:

- 1) the epimetrium: the thin peritoneal covering
- 2) the myometrium: the thick muscular layer
- 3) the endometrium: the inside of the uterus, the mucous membrane

The Menstrual Cycle

The endometrium shows cyclic changes from the time of puberty until menopause. These changes are known as the menstrual cycle.

At the beginning of the cycle the endometrium is thin (0.5mm thick). Under the effect of the oestradiol hormone secreted by the Graffian follicle of the ovary, it grows in thickness, blood supply and glandular tissue. When the ovum is extruded from the Graffian Follicle (ovulation) the follicle becomes yellow in colour and is known as the yellow body (corpus luteum), which secretes another hormone called Progesterone.

The progesterone affects the endometrium and makes it grow both in thickness, blood supply and gland formation. The thickness, reaches 7mm.

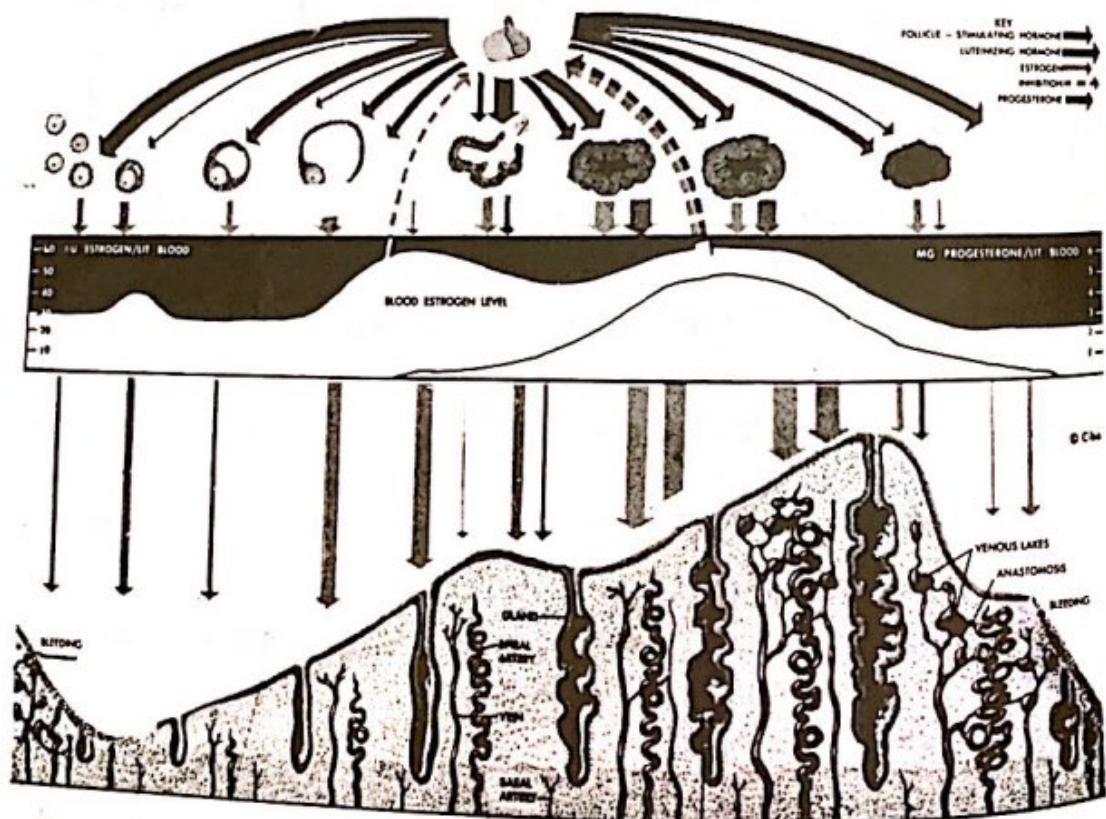
The Holy Quran has described these cyclic changes long before scientists came to know anything about it.

« الله يعلم ما تحمل كل أنثى . وما تغيض الأرحام وما تزداد وكل شيء عنده بمقدار » الرعد ٨

Sura 13/8:

“God knows what any female bears. He knows well to what extent the wombs may decrease and to what extent they may increase. To Him everything is well measured and balanced.”

Fig. 15



Menstrual and ovarian cycle

Secretory phase

The endometrial growth is cyclic. When it reaches its pinnacle, either pregnancy occurs and the growth continues or pregnancy fails and the whole endometrium is shed out, except the basal layer. This process of shedding is accompanied by bleeding, and is known as menstruation.

These cycles go on from puberty until menopause without cessation, month after month, except when pregnancy occurs.

Then, another cycle occurs. The growth continues until term and delivery of the baby. Another shedding of the inside of the uterus occurs; the bleeding that occurs after delivery of the baby is known as lochia. The time for healing of the inside of the uterus and the changes that lead to the uterus coming back to pre-pregnancy condition, is known as puerperium.

These cyclical changes of the uterus were mentioned in the previous Quranic aya (Sura 13/8).

Ibn AlQaim in his book *Al Tibyan Fi Aqsam Al Quran* described the spongy character of the inside of the uterus.

The Ovarian Cycle

The cyclical changes of the uterus just described are a reflection of the cyclical changes that occur in the ovaries.

The proliferation of oocytes (primitive ova) until maturation and the shedding of one ovum every month, are periodic.

This cycle is repeated throughout the reproductive life of the female.

Under the effect of the pituitary hormone F.S.H., many primary oocytes will show growth, every month. However, not all of them will show maturity. Only one of them will do so. Occasionally two or more ova mature simultaneously. If they get fertilized, the mother will have unidentical twin pregnancy. The twins are only similar to each other, as much as ordinary brothers and sisters are. In identical twins, only one fertilized ovum divides into two separate individuals. They are identical because they are created through one fertilized ovum.

The rest of the oocysts (primary ova) will not mature and will eventually die.

The maturation of the primary ova into a follicle takes about 14 days.

By then, the pituitary gland will send another hormone (L.H.) which will make the follicle fill with fluid and rupture.

When it ruptures the ovum comes out surrounded by a wreath made up of cells known as "Corona radiata" or radiating crown.

The Fallopian tube will catch the ovum and allow it to enter inside its folds.

The follicle after the extrusion of the ovum becomes yellowish in colour and becomes known as Corpus luteum (Yellow body). This yellow body sends an important hormone which prepares the uterus for receiving the fertilized ovum. It also prepares the cervix (neck of uterus) and makes its thick secretions become thin and watery. The breasts and the whole body prepared for the expected pregnancy, by the hormone, Progesterone secreted by the yellow body.

If pregnancy occurs the yellow body will receive messages from the implanting ovum and will continue to grow and become Corpus luteum of pregnancy, until the placenta takes over its functions by the third month of pregnancy.

If pregnancy fails, the corpus luteum will shrivel and die and become the white dead body known as corpus albicans. This ends with menstruation or bleeding from the uterus, and a new cycle will start.

The ovum (egg) will now be carried inside the Fallopian tube by the cilia (hair like projections) present in the tube.

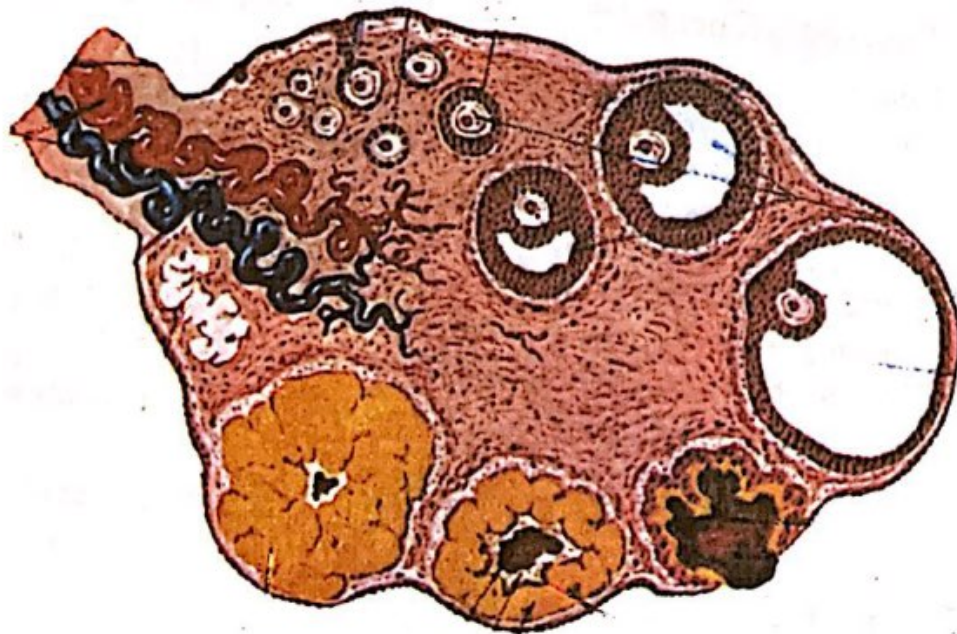


Fig. 16

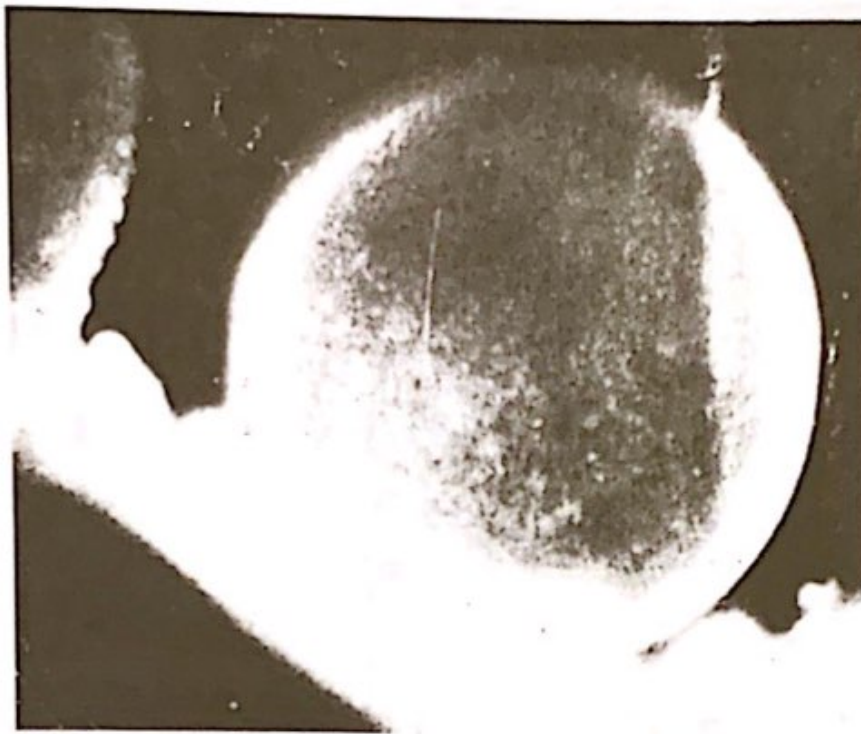


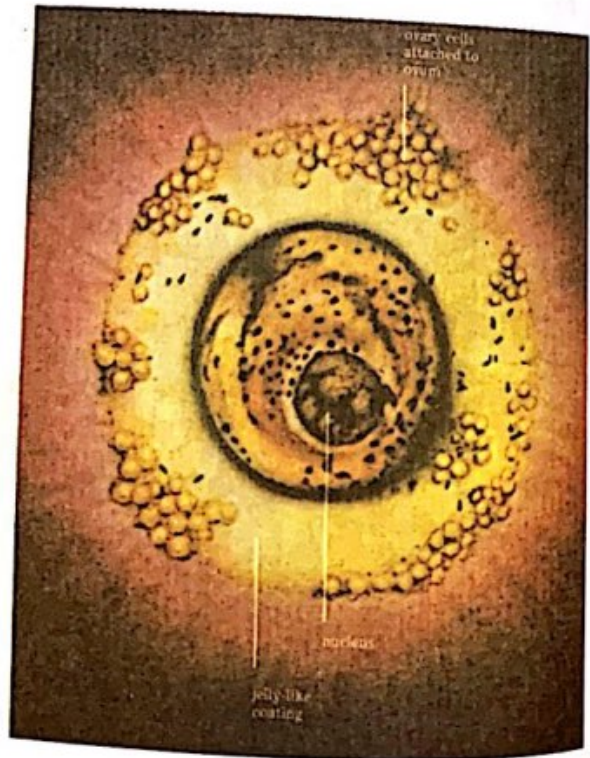
Fig. 17
The ovum after its expulsion from the ovary, the fimbria of the F. tube holds it and allows it to enter inside the tube.



Fig. 18
The extrusion of the ovum (egg) from the ovary
The ovum (egg) extruded is soon drawn into the Fallopian tubes by the
movements of the fimbriae of the funnel ends of the F. tube.



Fig. 19
The fimbria of the Fallopian tube.



The ovum (egg) or Female Nuttuh

Fig. 20
The ovum surrounded by the "Corona radiata" (radiating crown) which is made of cells accompanying it from the ovary. This crown helps to attract sperms. At fertilization it is discarded, as it is not needed any more.



Fig. 21
 An unfertilized ovum in the folds of the Fallopian tube. It is surrounded by cells forming the Corona radiata. The folds of the tube secrete enzymes which will loosen this envelope. The ovum will remain in the Fallopian tube for 12 hours, waiting for sperms to come. If none has arrived, it will die and will be extruded by the tube to the uterus, and will be shed out with the menstrual blood.
 (middle), and many will die without having entered (right).

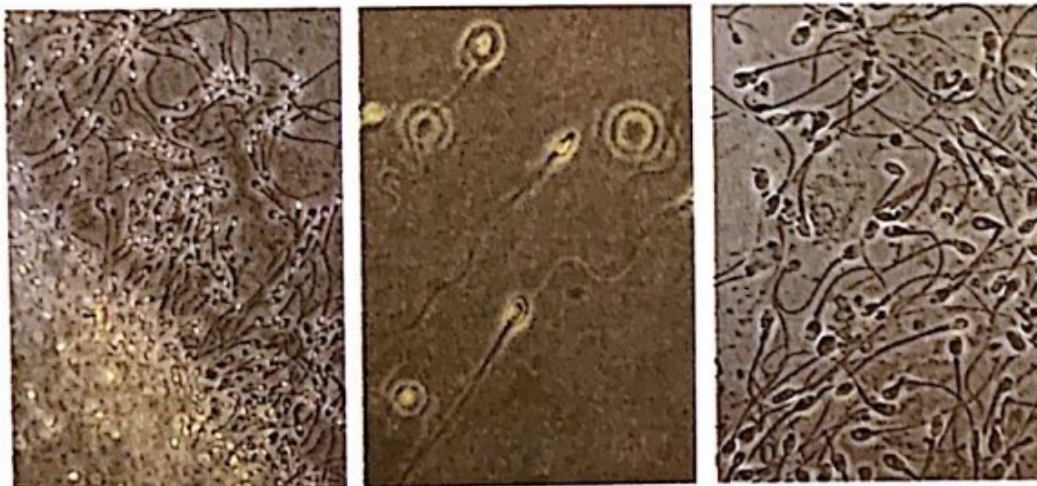


Fig. 22
 The cervical mucous is thick before the time of ovulation. Most of the sperms shown here die (3) and fail to penetrate the thick mucous.

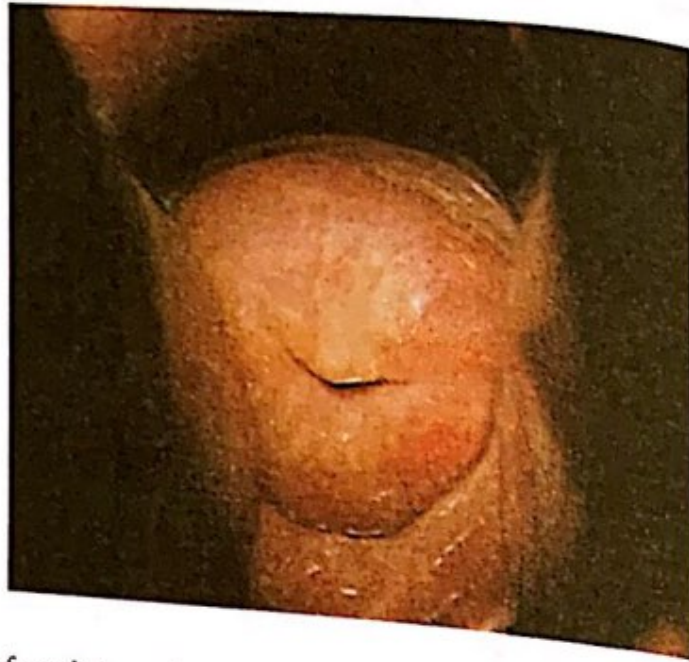

Fig. 23
At the time of ovulation, the cervical mucous is thinned and becomes like water jelly. The sperms can penetrate the cervix through the opening. The thinning of the cervical mucous is affected by the progesterone hormone secreted by the yellow body (Corpus luteum) after ovulation.

Meiosis or Reduction Division

If Coitus occurs at this time, the sperms will pass through the vagina to the uterus, probably by the contractions of the uterus. In a few minutes they will reach the Fallopian tube.

Only few (about 400) out of the hundreds of millions of sperms ejaculated will be capable to make this journey.

The sperms and the ovum would already have undergone meiotic division, by which the number of chromosomes will be halved. The final reduction division of the ovum is completed when the sperm reaches the ovum.

The *Chromosomes* are filaments made up of D.N.A. (Deoxyribonucleic acid) in double strand helix. They contain the genes which determine every type of characteristics, the body and cells have.

In each human cell, 23 pairs of these Chromosomes are found.

In the testes and ovaries, reduction division occurs whereby the 46 Chromosomes are reduced to 23 only.

The reduction division serves a function whereby the new individual gets 46 chromosomes from both parents; half from the mother (ovum) and half from the father (sperm).

The fertilized ovum contains 46 Chromosomes.

During meiosis (reduction division) another phenomenon occurs, whereby some bits of Chromosomes containing genes are crossed to another, so that the 4 sperms that result from the division of one sperm mother (primary Spermatocyte) are unlike each other.

That is why each individual is different from the other. Brothers and sisters resemble each other in many ways, but still they are different.

Only identical twins are similar to each other. Nevertheless, there are occult differences between them that make them two different persons and not one.

The Chromosomes "The Blueprint"

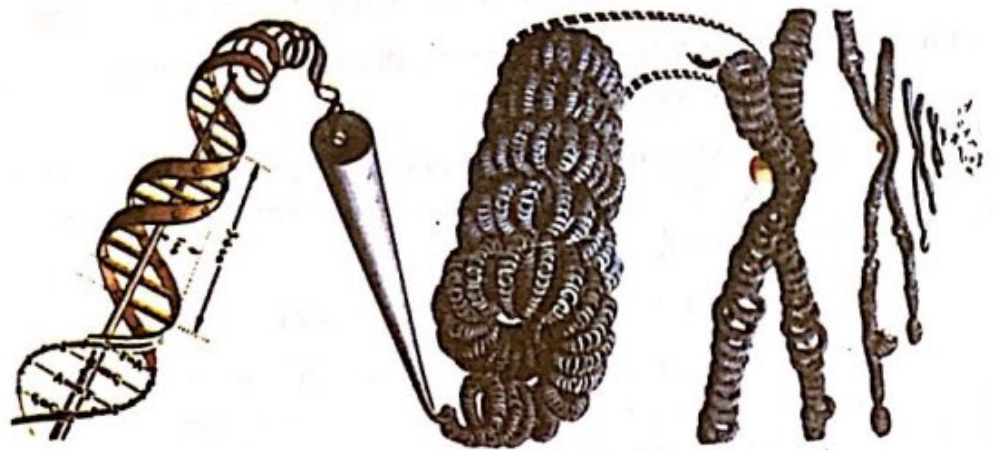
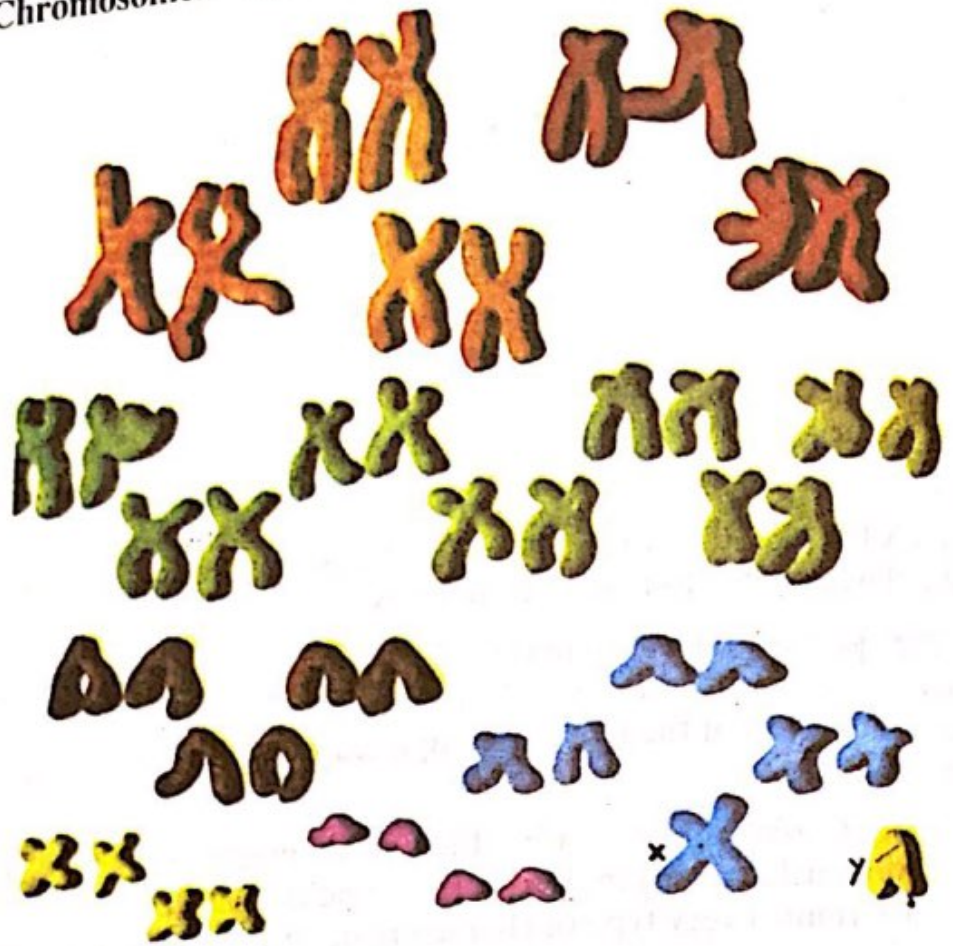


Fig. 24

The Chromosomes are thin long spiral "double helix" chemical substances found in the nucleus of each cell. The double helix chemical nature was first described by Nobel prize winners Crick and Watson in 1953. It is essentially made up of 4 nitrogenous bases arranged in a ladder form. Adenine always combines with thymine, and cytosine with

Guanine. A=T, and G=C. Each of these four nitrogenous bases will attach to Pentose Sugar; the sugar is attached to a phosphate substance. Any three of these nitrogenous bases will form a codon. There are millions and millions of genes in each cell. A human body consists of 6 million million cells.

A lot of secrets are hidden within these very very tiny particles called genes.

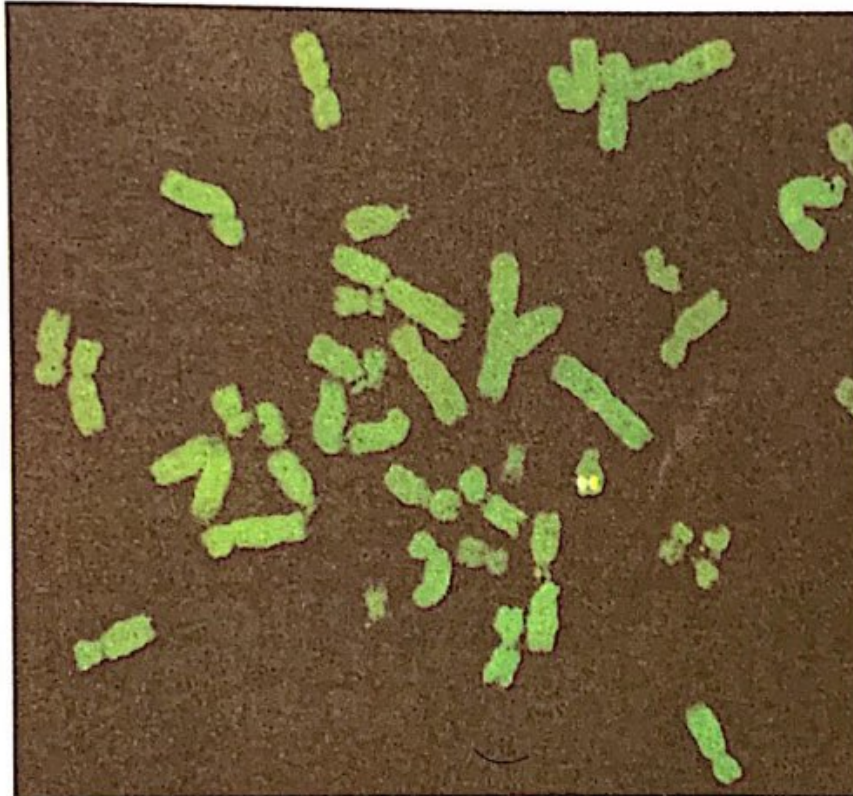

Fig. 25

A dividing human cell. It contains 46 Chromosomes, which are usually arranged in pairs. 22 pairs form the body or somatic chromosomes. One pair form the sex chromosomes. In males it is made up of one Y and one X chromosome, while in females it is made up of two X chromosomes.

Here the Y chromosome is the tiny short-armed gleaming chromosome, as it is made to fluoresce under the ultra violet light by a fluorescent substance attached to it.

Fertilisation

The ovum remains in the Fallopian tube up to 12 hours. If it is not fertilized by a sperm, it will die and be extruded.

The sperm and ovum are both capacitated in the Fallopian tube i.e. they acquire the ability for fertilization.

About 400 sperms reach the ovum, but only one of them is chosen by God, to fertilize it.

The factors which make one sperm succeed while the other fails are not yet known.

Once the sperm unites with the ovum and discharges its genetic material stored in its head, the ovum builds a thick wall that will not allow further sperms to penetrate.

It is clear that one sperm out of millions and probably billions is chosen for the fertilization of the ovum.

Similarly one egg is chosen to mature out of thousands that will eventually die monthly in every cycle.

The Quranic verse Sura 32/8 reads:

“And God made his (i.e. man’s) progeny from a quintessence of despised fluid.”

The Prophet Mohammad (peace be upon him) says:

“Not from the whole fluid (ejaculated) man is made, but only from a small portion of it.” (Narrated by Muslim.)

At least one quarter of the sperms die in the vagina, before they enter the neck (cervix) of the uterus. Millions of defective sperms which constitute 10 to 20 per cent of the whole sperm population also will die before starting the journey.

Some sperms are eaten by the female defence system in the cervix and vagina. Normal sperms swim towards the opening of the uterus (Cervical external OS), up the stream and away from the vaginal acid medium.

In the cervix there is a screening device through which the defective sperms are not allowed to swim. Only healthy sperms are allowed to swim in streams and channels formed by cervical secretions. The sperms swim in teams in each channel. Up the uterus and then into the Fallopian tubes.

Here the sperms get capacitated. Only a few hundred reach the end of the Fallopian tube. The smallest cells of the body (the sperms) meet the largest cell (the ovum).

The ovum begins to roll slowly like a planet out in space in a counter clockwise rotation, the same as that of the electrons around the nucleus of the atom or the earth around the sun.

It is interesting to know that Muslims making Tawaf (worship in Ka'aba at Makkah) go in swirls in counter clockwise fashion. It seems, as if the ovum, just before it is fertilized, goes into the same swirling counter clockwise fashion, like Tawaf.

Every atom, and every planet show the same strange phenomenon.

قال تعالى : « تسبح له السموات السبع والأرض ومن فيهن . وإن من شيء إلا يسبح بحمده ولكن لا تفقهون تسبيحهم » الاسراء ١٧ / ٤٤

Sura 17/44:

“The Seven Heavens, the earth, and whatever they contain, extol his limitless glory; but you men fail to understand their way in glorifying Him.”

وقال تعالى : « وكل في فلك يسبحون » يس ٤٦ / ٤٠

Sura 36/40

“All (things) float in their orbits.”

The chosen surviving sperm then penetrates the ovum, and delivers its genetic material to the ovum. This is the moment of conception. The main results of fertilization are:

- 1) Restoration of the diploid number of Chromosomes (i.e. the Zygote containing 46 chromosomes).
- 2) Determination of the sex of the new individual. An X-carrying sperm will produce, by God's will, a female, while a Y-carrying sperm a male embryo.
- 3) Initiation of cleavage or cell division of the zygote.

Cleavage

The zygote divides into two cells within 24 to 30 hours. From now on, the division will occur at a rapid pace. The 4 cell state is reached within 40 hours, and within 60 hours the 12 cells stage is reached.

This becomes like a mulberry and hence given the name morula.

At the fourth day the morula grows and becomes filled from the inside with a fluid, transforming it into the blastula (ball like stage).

Human blastula were recovered from the uterine cavity at the fourth and fifth day.⁽²⁾

At the sixth day implantation of the blastula into the endometrium of the uterus occur.

Ibn Hajar Al Asqalani in "Fateh Albari,"⁽³⁾ who lived six centuries ago, says: "When the semen enters the womb it remains for six days before it is supported by the womb." He also quotes Ibn Al Qaim (13th century) saying "When the semen enters the womb it forms a ball like structure which remains for six days before it gets attached to the womb."

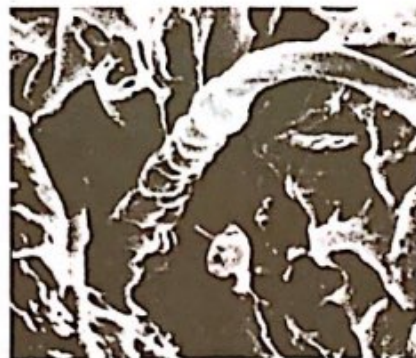
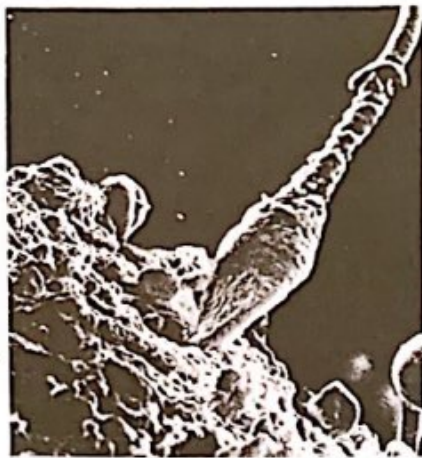

Fig. 26

Fertilization, formation of the "Zygote"

"Nutfatul Amshaq"

The chosen sperm approaches the ovum. Its head penetrates the wall and delivers the genetic material it contains. Once this union is accomplished, the zygote is formed.

The ovum will form a thick wall that will prevent further sperms from entering.

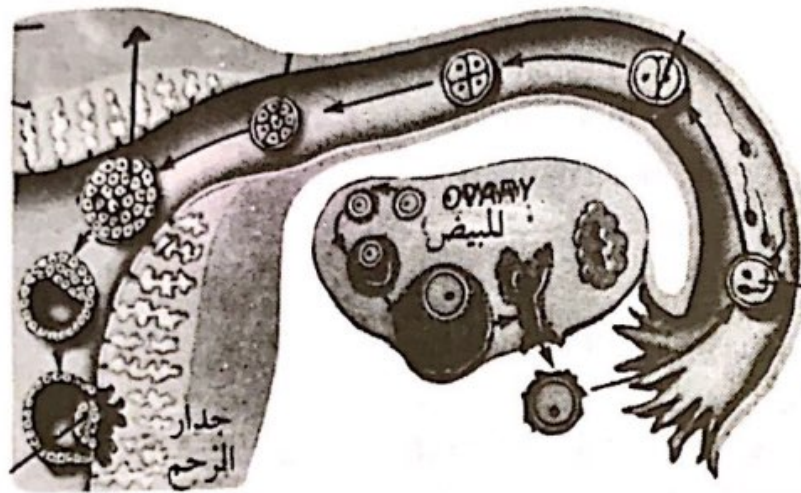


Fig. 27
 Schematic representation of ovary, uterus and Fallopian tube. The ovum (egg) is extruded from the ovary once every 28 days. It is fertilized by the sperm in the outer third of the Fallopian tube, forming the zygote, which starts division to form a mulberry like ball "Morula", which becomes filled with fluid from the inside, the blastula. This implants in the wall of the uterus.

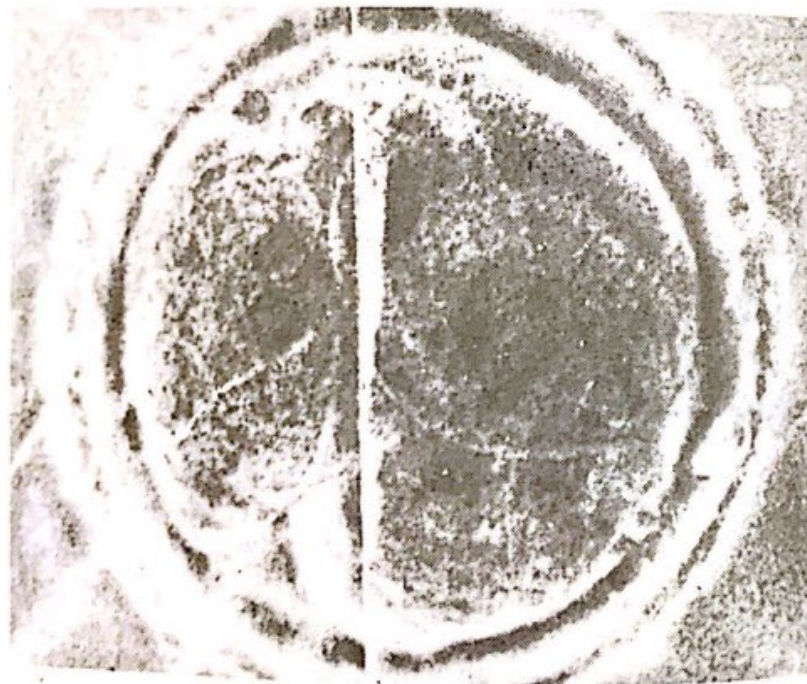

Fig. 28 The zygote (the fertilized ovum) starts to divide into two cells within 24¹⁰ 30 hours. The 4 cell stage is reached within 40 hours.

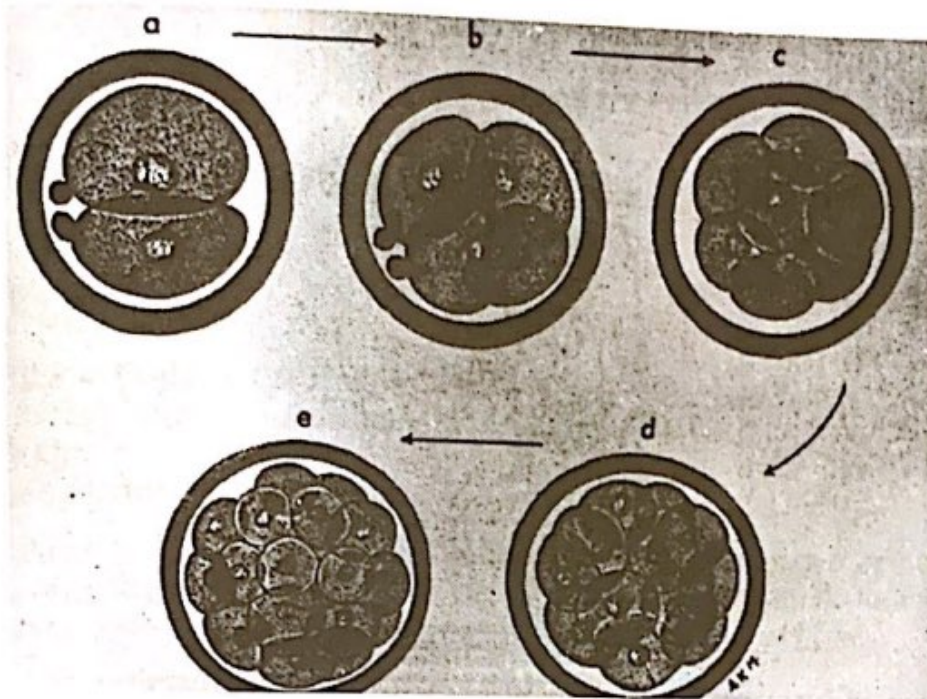


Fig. 29

Schematic representation of cleavage

a/ 2 cells stage (24 hours after fertilization)

b/ 4 cell stage (40 hours)

c/ 8 cell stage

d/ 12 cell stage (60 hours). This is called the morula

e/ 32 cell stage (3 days). It is still a morula or mulberry.

REFERENCES

- 1) Langman: Medical Embryology, 3rd Edn Page 9
- 2) Langman: Medical Embryology, 3rd Edn Page 29
- 3) Ibn Hajar Al Asqalani: Fatch Albari Sharah Sahih Al Bokhari, Vol II/481 Al Motbaa Assalagyiah

A BRIEF LOOK INTO THE HISTORY OF EMBRYOLOGY

In order to evaluate the Embryological data in the Holy Quran, we have first to look into the human knowledge of this subject at the time when the Holy Quran was revealed to Mohammad (Peace be upon him) 14 centuries ago, down to our time.

Aristotle (384-322 B.C.) wrote the first known treatise on embryology, in which he described the development of the chick and other embryos.

At this time there were already two theories concerning the development of embryos. Vis:

- a) Preformed in the male semen, or the femal secretion in which they exist as miniature creatures which tend to grow inside the womb.
- b) Actual formation and creation from the menstrual blood.

Aristotle took sides with the second theory. The role of a male's semen in reproduction was limited to the role of a catalyst in which the menstrual blood coagulated. He actually said that it resembles the curdling of milk into cheese.

So great was the effect of Aristotle that nobody dared to challenge his views for many centuries. Redi in 1668 dealt a blow to this theory, and Pasteur 1864 wrote the final obituary to the doctrine of Spontaneous generation.

However the Holy Quran and the Prophet Mohammad (Peace be upon him) challenged Aristotle, exactly 1100 years before Redi dared to put forward his theory.

In Sura 76 Verse 2 the Quran says:

“Verily we have created man from a drop of mingled liquids” (of both male and the female).

The Prophet was asked by a Jew: “O Mohammad, tell me from what thing man is created”. He replied, “O Jew. Man is created from both the fluids of male and female”.

Ibn Abbas, the cousin of the Prophet, when asked to explain the above verse (Sura 76/2), said: "the word Nutfatul Amshaq is the fluid of male and female intermingled and then it passes into many evolutionary stages" (Tafsir Ibn Garir, Tafsir Ibn Kathir).⁽¹⁾

None of the exegetes (interpreters of the Holy Quran) differ on this point. All agree to the above explanation. However, the effect of Aristotle was so great in the medieval era that even Muslim philosophers and men of science and medicine took his views.

This led to the squabble between the Ulema ("clergy men" though in Islam there is no such clergy as in other religions), and the Muslim physicians.

Ibn Hajar Al Asqalani⁽²⁾ who lived in the 14th century says "Many of the anatomists claim that the semen of the male has no role in creation of the baby. It's role, they claim, is limited to curdling the menstrual blood from which man is born. The sayings of the Prophet denies what they say. The semen of the male actually participates equally to that of female in formation of the embryo."

We find the same discussion brought forward by Ibn AlQaim⁽³⁾ who lived in the 13th century.

Galen (the 2nd century A.D.) was probably the first man to write a book on the subject of embryology. His book was titled "On the Formation of the Foetus". Nevertheless he stuck to Aristotle's view (just explained).

In the middle ages the Holy Quran and the Prophet Mohammad (Peace be upon him) (570-632 A.D.), revealed many astonishing facts about the creation of man, especially in the field of embryology. These will be dealt with later in some detail.

Keith Moore⁽⁴⁾ in his book "The Developing Human", 3rd Edition, mentioned few of these astonishing revelations as revealed in the Holy Quran.

Until the 18th century it was generally believed that a fully formed animal exists in miniature in the egg needing only the stimulus of the sperm to initiate growth and unfolding, or that similarly pre-formed organisms, male and female, constitute the sperms and these merely enlarge when they get inside the womb. (Fig. 1).

The original pre-formation theory was virtually destroyed by Wolff (1759-69) who described globules (cells) in the egg from which the embryo was built gradually, step by step, starting from the shapeless

globules to the more complex human embryo. This phenomenon was called epigenesis.



Fig. 30 Human sperm containing a miniature human being, drawn by Hartsoecker (1694), Paris, from "essay de Dioptrique", illustrating the pre-formation doctrine that prevailed during the 17th century.

Many years elapsed before Wolff's views were accepted. The final blow to the original pre-formation doctrine was dealt by Driesch (1900) who separated daughter cells of a fertilized egg and allowed them to grow into complete embryos.

Pander in 1817 demonstrated the three primary germ layers in the chick embryo. Von Baer (1829-37) broadened this concept to all animals, and identified the human egg (150 years after Leeuwenhoek first discovered the human sperm). Von Baer was called the "Father of modern Embryology".

Cleavage, i.e. subdivision of the egg into building units of the embryo, was first described by Prevost and Dumas in 1824. However, its true meaning was not understood until Schwann and Schleiden (1839) put forward the doctrine of cells as being the biological units from which the whole body of animal or plant is built. Twenty years later the eggs and sperms were recognised as cells.

Hertwig in 1875 was the first to describe scientifically the fertilization of an egg by a sperm.

Von Benden 1883 proved that male and female cells contribute the same number of chromosomes to the embryo.

It is quite astonishing to find that the Holy Quran and the Prophet Mohammad (570-632) (Peace be upon Him) has stated emphatically that:

- 1) Both male and female contribute equally to the formation of human embryo.
- 2) That the human embryo is not preformed but is created in stages.

These facts are stated in the following verses and Hadith.

Sura 76/2

“Verily we have created man from a drop of mingled fluids”

The Prophet said:

“O Jew. Man is created from a drop of male semen and a drop of female secretion”. « مسند أحمد بن حنبل »

Sura 71, Verse 13-14:

“What is amiss with you that you cannot look forward to God’s Majesty. He has created [every one of] you in successive stages.”

Sura 23/12-14:

“We created man from the quintessence of mud. Thereafter we cause him to remain as a drop of sperm in a firm lodging (i.e. the womb). Thereafter we fashioned the sperm into something that clings (Alaqa), which we fashioned into a chewed lump (Modgha). The chewed lump is fashioned into bones which are then covered with flesh. Then we nurse him unto another act of creation. Blessed is God, the best of artisans”.

Sura 22/5:

“O men! If you are in doubt as to the resurrection, remember that, We have created (everyone of) you out of dust, then out of a drop of semen, then from something that clings (Alaqa) then from a chewed like lump (Modgha), which differentiates (and either abort or complete its growth). We rest whatever We want in the womb to the time We decide to bring you forth as infants”.

These stages viz:

- 1) Nutfa: “a drop of fluid”
- 2) Alaqa: “something that clings or attaches itself”
- 3) Modgha: “a chewed lump”

will be discussed later.

The emphasis here is on the Quranic expression of the human embryo being formed in many successive stages expressed as Nutfa, Alaqa, Modgha, and each stage is further subdivided and explained in different verses of the Holy Quran, the Hadith of Prophet (peace be upon Him) and the exegesis of the different commentators of the Holy Quran.

These astonishing revelations were not known until recently. The epigenesis doctrine i.e. creation of human embryo in successive stages were first put forward by Wolff (1759-69) and only became recognised and accepted late in the 19th and early 20th centuries.

The accuracy of the descriptive terms used in the Holy Quran will be dealt with later. Here we emphasize that these details were never known until the 20th century.

REFERENCES

- 1) (a) Ibn Garir Al Tabri "Jamiel Bayan Fi Tafsir Al Koran" Sura 76/2
(b) Ibn Kathir "Tafsir Al Koran Al Azeem" Sura 76/2
- 2) Ibn Hajar Al Asqalani "Fateh Al Bari Shareh Sahih Al Bokhari". Bab Alkadar, Vol, II, Page 480, AlMat'ba Assalafiyah, Cairo.
- 3) Ibn AlQaim "Al Tibian Fi Aqsam Al Quran" Page 244, 256
- 4) Keith Moore "The Developing Human" 3rd Edition 1982, P8

For Further Reading

- 1) Leslie Arey "Developmental Anatomy" 7th Edition, 1974
- 2) Keith Moore "The Developing Human" 3rd Edition, 1982
- 3) Hamilton, Boyd and Mossman "The Human Embryology" 4th Edition, 1976

The Nutfa

The Nutfa literally means “a drop of fluid.” In the Quran and Hadith (sayings of the Prophet Mohammad, Peace be upon him) it is used in three different but interwoven connotations:

1. The male Nutfah (the male gamete).
2. the female Nutfah (the female gamete).
3. The intermingled and mixed “nutfatul Amshaq” which is made of the complete mixing and mingling of the male with the female Nutfah.

We will discuss here the different meanings of Nutfah as expressed in the Holy Quran and Hadith; and also discuss the Quranic verses which mentioned the semen or the male fluid.

The word Nutfah was mentioned twelve times in the Holy Quran and the word Manii “Semen” was mentioned three times. Male fluid was mentioned many times in the Quran expressed as “Despised liquid”, « ماء دافق » “an ejaculated spurting liquid” « ماء مهين »

The Male Nutfah

قال تعالى : « أَيْحَسِبُ الْإِنْسَانُ أَنْ يَتْرَكَ سَدَى ؟ أَلَمْ يَكْ نَظْفَةً مِنْ مَنَى يَمْنَى . ثُمَّ كَانَ عِلْقَةً فَخَلَقَ فَسَوَّى فَجَعَلَ مِنْهُ الزَّوْجَيْنِ الذَّكَرَ وَالْأُنْثَى .. أَلَيْسَ ذَلِكَ بِقَادِرٍ عَلَى أَنْ يُحْيِيَ الْمَوْتَى » . القيامة / ٣٦-٤٠

Sura 75/36-40:

“Does man think that he is left to himself to waste his life!! Was he not a mere sperm (drop of fluid) out of Semen that has been ejaculated? Thereafter, he became Alaqa (into different organs) and gave its form and shape. And He out of the Semen, made both sexes the male and the female. Is He not then able to bring the dead back to life?”

Sura 53/45-46:

“God fashioned both male and female from a drop of fluid that has been ejaculated.”

«وانه خلق الزوجين الذكر والأنثى من نطفة اذا تمنى»

Sura 59/58-59:
"Have you ever considered the semen that you ejaculate? Do you create it or are We the creators?"

انرايتم ما تمنون أنتم تخلقونه أم نحن الخالقون؟ الواقعة ٥٧/آية ٥٩-٥٨

In these three Suras, there are a lot of facts that require careful consideration, viz:

1. The sex of the new born is determined by the male. It is definitely stated that the male and the female are fashioned from a drop of fluid from the semen that has been ejaculated.

It is a common knowledge that Semen is the fluid ejaculated by a male during sexual acts. Females do not possess such ejaculated semen.

We know now that the sex of the new born is determined by the sperm which will fertilize the ovum. If the sperm carrying an X chromosome, fertilizes an ovum (which always contains an X chromosome), the offspring will be a girl, while if the fertilizing sperm contains a Y chromosome, the offspring will be a boy.

The Quran has stated this fact 1400 year ago, before anybody knew anything about X or Y chromosomes.

2. The second important point, which is stated clearly in the Holy Quran is that only a small portion of seminal fluid participates in forming the embryo.

الم يك نطفة من منى يمى - « وأنه خلق الزوجين الذكر والأنثى من نطفة اذا تمنى »

"Was he not a mere "drop of fluid" out of semen that has been ejaculated?" "God fashioned both male and female from a drop of fluid that has been ejaculated".

We know now that the sperms constitute only 0.5 per cent of the total semen ejaculated. Nevertheless each ejaculation of semen contains an average of 200 to 300 million Spermatozoa.

Only one of this huge number fertilizes the ovum to form the zygote which grows into a baby.

In another Sura, God says:

"God made his (i.e. man's) progeny from a quintessence of despised liquid". Sura 32/8

ثم جعل نسله من ماء مهين
السجدة ٣٢ / آية ٨

The Prophet Mohammed (Peace be upon him) said "Not from the whole fluid (ejaculated), man is made, but only from a small portion of it" (Narrated by Muslim). (رواه مسلم)

These facts were never known until quite recently.

The Female Nutfah

The female Nutfah per se is not mentioned clearly in the Holy Quran. It is inferred from the "Nutfatulamshag" i.e. the mingled Nutfah from both male and female partners. However it is clearly mentioned in the Prophet's sayings "the Hadith" where Ahmed Ibn Hanbal narrates that a Jew has asked the Prophet the following question:

"O Mohammed. Tell me from what thing man is created".

The Prophet answered, "O Jew. From both male Nutfah and female Nutfah man is created".

The exegesis of the Holy Quran since the time of Ibn Abbas, the cousin of the Prophet, states clearly that a mingled Nutfah i.e. "Nutfatulamshag", is from both male and female Nutfah.

This is a very astonishing revelation, as it is only recently that we came to know that both male and female participate equally to the formation of the human (or animal) zygote.

Not until Hertwig in 1875 observed that both the male sperm and female ovum participate in the formation of the zygote, that anybody has said anything about this fact.

Van Benden in 1883 proved that both male and female participated equally in the formation of the human zygote.

Prior to the discovery of Hertwig and Boveri, there were hot discussions between those who claim that the whole embryo is made from the ova, the ovist, and those who claim that it is wholly made from the male sperm.

In fact they believed that the embryo is already pre-formed either in the female's egg (ovum) or in the male sperm.

The Quran and the Hadith have clearly revealed these unknown facts, long before they became discovered by the scientists of the 19th century.

"Nutfatul Amshag" "the Mingled Nutfah" from both male and female partners. It is clearly stated in Sura 76/2:

«انا خلقنا الانسان من نطفة امشاج نبتليه فجعلناه سميعا بصيرا»
الانسان ٧٦ / آية ٢

“Verily, We have created man from a drop of mingled liquids”.

The Prophet and the commentators of the Holy Quran explicitly said that the mingled liquids are from male and female partners equally shared and mingled.

In the previous article “the history of Embryology” we concisely mentioned how the human efforts culminated in the recognition of the role of both ovum and sperm in the formation of the human embryo. This was definitely proved late in the 19th and early in the 20th centuries.

The Quranic verses stand out as a remarkable revelation never known to humans before the 19th century.

Preformational or Epigenetic

“THE ROLE OF GENES”

التقدير في النطفة

عبس ٨٠ / ١٧-١٩

«قتل الانسان ما اكفره . من أي شيء خلقه من نطفة خلقه فقدره» .

Sura 80/17-19

“Does man ever consider out of what substance God created him? Out of a drop of fluid (Nutfah) He created him, in which he determined his nature”.

The Quranic revelations speak of two forms of development of the human embryo: i] *epigenetic* in which the “Nutfatulamshag” “the zygote” develops into “Alaqa” i.e. something that clings or attaches to the uterus (womb). The Alaqa is then transformed into “Modgha” i.e. a “chewed lump” which in embryology is recognised as the “Somite-stage”. The somites then differentiate into bones and muscles that encloth the bones. Then the human embryo is reshaped. God is blessed, the best of artisans.

ii] *Preformational* in which the characteristics and nature of the forthcoming human being is already predetermined in the Nutfa itself (male and female gametes).

Leslie Arey⁽¹⁾ in Developmental Anatomy states the following: “The present view on these matters is that development is strictly preforma-

tional as regards the genes and their hereditary influences, but vigorously epigenetic in actual constructional activities". All the authorities of Embryology agree to this fact (Keith⁽²⁾ Moore), Hamilton, Boyd and Mossman⁽³⁾, Jan Langman⁽⁴⁾, Bradley Patten⁽⁵⁾.

A bedouin Arab told the Prophet that his wife has delivered a black boy while he and his wife were not blacks. He wanted to deny the child. The Prophet asked him: "Have you got camels?" The man said yes, I do. The Prophet asked What is their colour? He said reddish yellow; and the Prophet asked: Is there any blackish one in them? And the man agreed. The Prophet then asked the man: How does it acquire this colour? The man said: It must have been inherited somehow? The Prophet said: Then your child might have inherited this blackish colour from his ancestors". (Narrated by Bokhari, Moslim and others).

The Quranic revelations and the Hadith of the Prophet as exemplified in the above mentioned incident narrated by all Six highly esteemed books of Hadith "the sayings and deeds of the Prophet", clearly indicate that the Quran and the Prophet Mohammad (Peace be upon him), mentioned many scientific facts regarding the formation of the human embryo that were never known except in the Twentieth century.

That man is determined (a better word than preformed which is used by the embryologist of today) at the level of Nutfa (male and female gametes) and then developed into subsequent stages (i.e. epigenesis), is only understood recently by modern embryologists:

The Holy Quran and Hadith of the Prophet had already revealed these facts 14 centuries ago.

The Prophet said:

"God has ordained an angel that accompanies the different stages of development of the Nutfa. The Alaqa, the Modgha and in every stage he asks God: O God, what to do next? If God determines its full development, the angel asks: Is it a boy or a girl? happy or unhappy, his livelihood and his life span. All is written (determined) while he is in his mother's womb". Narrated by Bokhari and Moslim.

In another Hadith narrated by Moslim, "the Prophet states that the angel enters the womb at 40-42 days from fertilization and gives the Nutfa its shape and form, creates its hearing and visual apparatus, builds up the bones, the muscles and forms the skin. He then asks O God, is it a boy or a girl, what is his livelihood and what would be his life span? God gives the answer to the angel who writes all that would come".

REFERENCES

1. Lesly Arey: Developmental Anatomy, 7th Edition, 1974, P 5
2. Keith Moore: "The Developing Human", 3rd Edition, 1983
3. Hamilton, Boyd and Mossman "Human Embryology" 4th Edition, 1976
4. Jan Langman "Medical Embryology" 3rd Edition, 1975
5. Bradly Patten "Foundations of Embryology" 3rd Edition

ALAKAH (Alaqa)

The Arabic word Alakah literally means something that clings or attaches to something else. The word also means a leech. The medical leech has been notorious for its clinging property to the skin whereby it sucks blood, a phenomenon that was often used in medicine as a remedy (blood letting). It also has a meaning seldom used in Arabic and that is a clot or congealed blood.

This shows why there is always difficulty in translating the Quran into other languages because the Arabic word may have half a dozen meanings and the different commentators of the Holy Quran chose one or another meaning.

The word Alakah was mentioned in the Holy Quran five times. These are in Sura 22 verse 5, Sura 75/36-40, Sura 40/67 and Sura 96/1-3.

As soon as fertilization has been accomplished by the sperm, the fertilized ovum goes into successive divisions forming smaller cells called blastomeres. On the third day 12-16 such cells are formed in a mulberry like fashion and hence the name morula, which grows and becomes filled with fluid from the inside forming a ball. The ball like structure is called blastula and the cavity filled with fluid is called the blastocoele. The blastula is only 0.1 mm in diameter.

As the fertilization usually occurs in the outer third of the uterine tube, there must be some means of propulsion to carry the fertilized ovum into the uterus. The morula and blastula has no means of propulsion. It is a passive ball like structure which is gently moved by the cilia of the uterine tube itself.

That is why when the cilia are damaged by inflammation it ends in sterility.

The blastula reaches the uterus in 4 to 5 days and lies free in the uterine secretions for a further 2 days before it clings and gets implanted into the uterine wall (usually the upper third of the posterior wall as it is the most suitable part for implantation).

It is amazing to find Ibn Hajar Al Asqalani ⁽¹⁾ in his highly esteemed book "Fatah Albary Sharah Sahib Albokhari" saying "When the semen enters the womb, it remains for 6 days before it is supported by the womb."

He also quotes Ibn AlQaim (13th century) saying "When the semen enters the womb it forms a ball like structure which remains for 6 days before it attaches itself to the womb."

As the fluid increases in the blastula (blastocyst) it separates the cells into 2 layers: an outer cell layer made of cells concerned with nutrition, called trophoblasts and an inner cell mass which later grows into the embryo.

IMPLANTATION OR FORMATION OF THE ALAKAH (Alaqa)

The blastocyst's outer layer cells attach themselves to the endometrial epithelium (inner most layer of the uterus) by hair like projections which inter-digitate with similar projections from the endometrial epithelial layer.

As soon as this hinging and clinging occurs, the trophoblast (Outer layer of the blastula) proliferates and forms a mass of cells that interdigitate and lose its cell boundaries (called Syncytiotrophoblast). These finger like processes invade the endometrial epithelium and endometrial stroma. By the end of the first week, the blastocyst is superficially implanted in the compact layer of the endometrium.

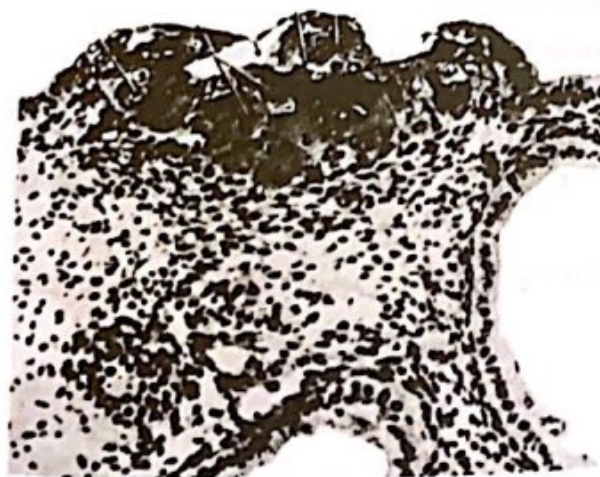

Fig. 31
The recently implanted blastula is only 7½ days old.

This process of clinging, attachment and implantation is expressed in the Quran by one elegant word Alakah 14 centuries ago, long before any man has known anything about this amazing process.

The finger like processes of the Syncytiotrophoblast invading the endometrium soon become surrounded by lacunae (small lakes) of blood.

The nutrient material seeps through these lacunae into the growing embryo.

The endometrium under the effect of progesterone secreted by the corpus luteum (now corpus gravidarum), grows remarkably, its glands become more tortuous and its cells more abundant.

There are about 15,000 uterine glands which secrete a liquid called "Uterine milk" that nourishes the fastly growing blastocyst.⁽²⁾

An amazing phenomenon is occurring here. A new organism is growing inside the uterus, half of it is completely foreign to the body and yet not rejected. How the immune defence system of the body is muted towards the invading blastocyst is not fully known. It has been only recently discovered that the finger like processes of the blastocyst are coated with maternal protein called transferritin. This coating disguises the blastula, the body defence system of the mother considers them as part of self, and hence, is not rejected.⁽³⁾

The same process was discovered to be found in tumour cells and parasites invading the body like Schistosomiasis.

The transferritin is not the only maternal protein which protects the embryo from the immune system of the mother. There are also blocking antibodies.

The trophoblast itself produces a unique protein called (Trophoblast Anti immune antigen): TA.1, which has an amazing property of abolishing the immune reaction of the host tissue.

T.A.I is also produced by the amnion surface cells i.e. where the growing embryo comes into contact with maternal tissue.

The implantation process of the blastocyst into the endometrium takes 5 days i.e. from the 7th to the 12th day and we quote Keith Moore in his book "The Developing Human" saying "The implantation of the blastocyst is the main characteristic of this stage."⁽⁴⁾ Hertig in 1968 described the Syncytiotrophoblast as "invasive, ingestive and digestive."

At the 10th day from fertilization, the blastocyst is completely embedded in the uterine endometrium, the defect in the surface is plugged by blood clot and cellular debris. By the 12th day this plug is

replaced by regenerating epithelium and a minute elevation on the endometrial surface is noted.

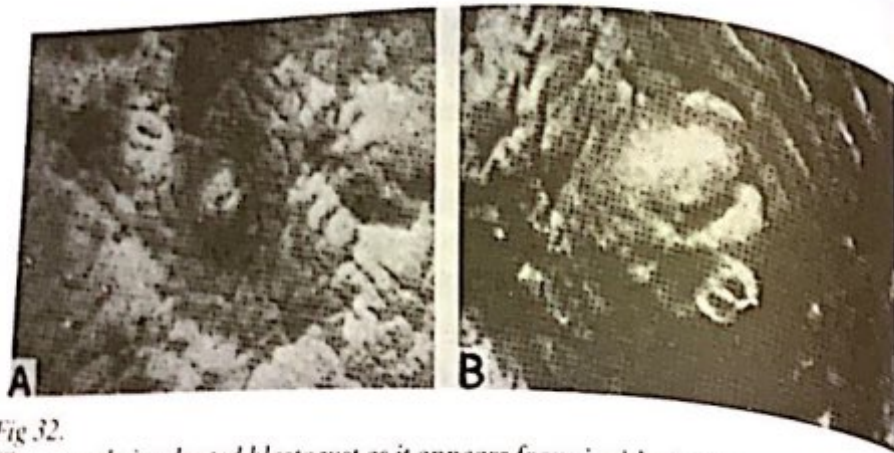


Fig.32.
The recently implanted blastocyst as it appears from inside the uterine cavity on the 12th and 14th day.

It is very impressive indeed to find the Holy Quran describing this phenomenon which is only very recently discovered.

قال تعالى :
« الله يعلم ما تحمل كل أنثى وما تغيض الأرحام وما تزداد وكل شيء عنده
بمقدار » الرعد ٨

Sura 13/8:

“God knows what any female bears in her womb. And by how much the wombs may decrease and by how much they may increase. For Him, everything is created in due proportion.”

The word “*Taghiz*” has two meanings literally⁽⁵⁾, one is to decrease, the other is to hide or disappear.

The second meaning will be considered here, i.e. hide or disappear. The first meaning was already discussed (Page 40).

The blastocyst tends to completely hide or disappear in the 10th day after fertilization, and not until the 12th day that a tiny elevation is seen on the surface of the endometrium.

This is exactly what has been described in the Quranic word *Tagheet* where the *alakah* disappears inside the womb.

The syncytiotrophoblast forms digital like processes called the villi (Chorionic villi) which arborate like a tree. Soon it covers the whole ball like blastocyst.

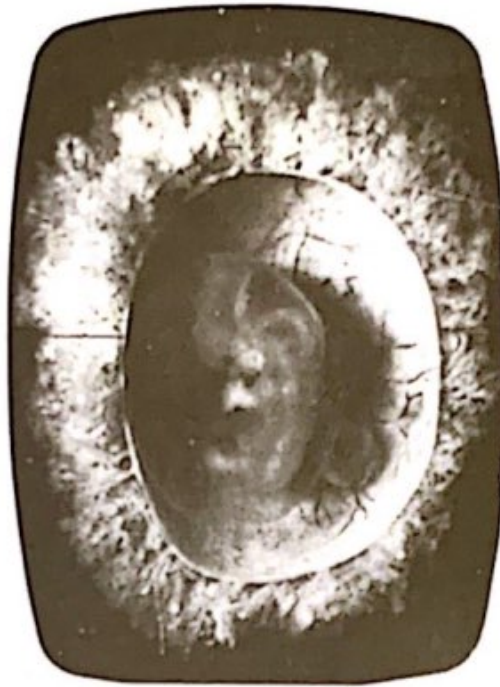

Fig. 33

The embryo is lying in the amniotic sac, which is surrounded, from all sides, by a ball of branching villi which anchor the embryo and the amnion to the uterine wall. The best term for it is Alakah.

The chorionic villi which are solid at first become invaded by a core of loose connective tissue, thus converting the primary villi into secondary villi at the 15th day. Soon blood vessels form inside these secondary villi, thus converting them into tertiary villi (15th — 20th day).⁽⁶⁾

Thus we see another type of anchoring and hinging of the embryo to the womb. Still there is no better descriptive term than Alakah.

As the embryo proper forms from the inner cell mass we see the third type of attachment or hanging between the embryo and the uterus.

The connecting stalk forms at the caudal end of the embryo. It connects the embryo proper and its coverings, the amnion and yolk sac to the outer wall of the blastocyst.

To sum up — we find from the 7th to 21st day three consecutive processes in which clinging is the most dominant feature.

- 1) From day 7, implantation of the blastocyst occurs. It becomes completely embedded by the 10th day.
- 2) The chorionic villi appear for the first time by day 13 and 14, and soon cover the whole blastocyst attaching the ball like structure to the uterus (womb) by the anchoring villi.

3) The connecting stalk connects the embryo proper (the embryonic disc) with its true coverings, the amniotic sac and yolk sac to the outer ball, the chorion.

Thus we find 3 different ways of clinging and attachment of the developing fertilized ovum to the womb of the mother.

There is no better word for this stage, which describes it eloquently than the Quranic word Alakah.

The real meaning of Alakah was not fully understood in the past. It has to wait for the medical and scientific achievements of the Twentieth century to be fully appreciated and deeply comprehended.

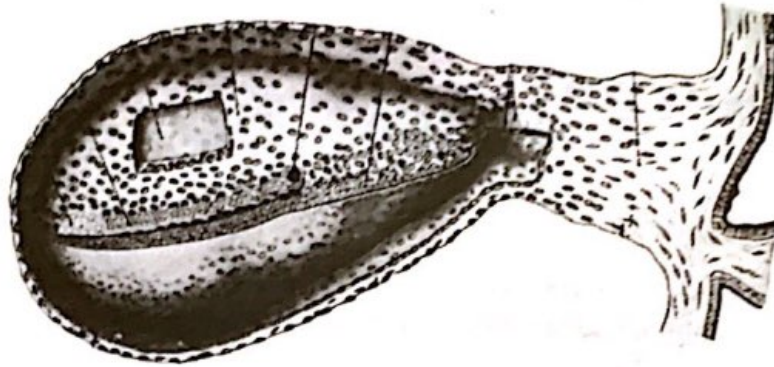


Fig. 34
Embryo at 18th day showing how it is suspended from its caudal end to the uterine wall by the connecting stalk. The chorionic villi anchor the outer ball to the uterine wall, thus forming multiple supportive anchorage for the embryo.

This is elegantly expressed by the Quranic word Alakah.

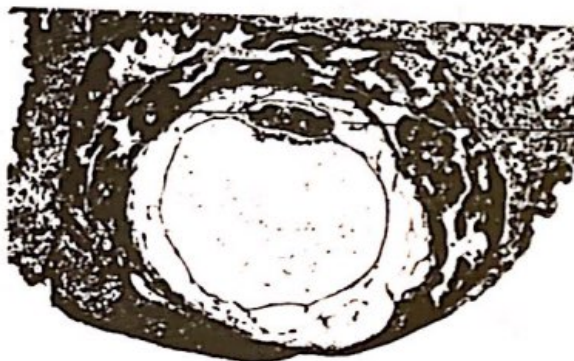


Fig. 35
An implanted blastula whereby the site of entry is plugged by fibrin and covered by

epithelium. The embryo proper is bilaminar, made of ectoderm and endoderm. The amniotic sac is only a small slit while the primary yolk sac is large. The outer ball made of trophoblastic cells invade the uterine wall forming multiple blood lacunae through which the nutrients pass to the newly formed embryo. This connection between the endometrium of the mother and the trophoblasts of the embryo form the Alakah.

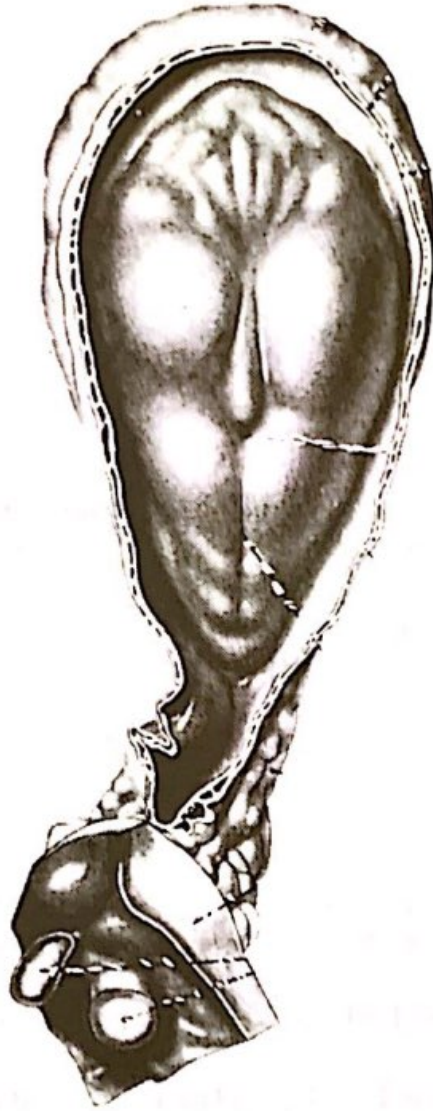


Fig. 36

An embryo 18 days old where the connecting stalk anchors the embryo from its tail end to the uterine wall (through the chorion.)

This is the third type of anchorage between the embryo and the womb.

No term is better than the Quranic Alakah, which describes this stage precisely and elegantly.

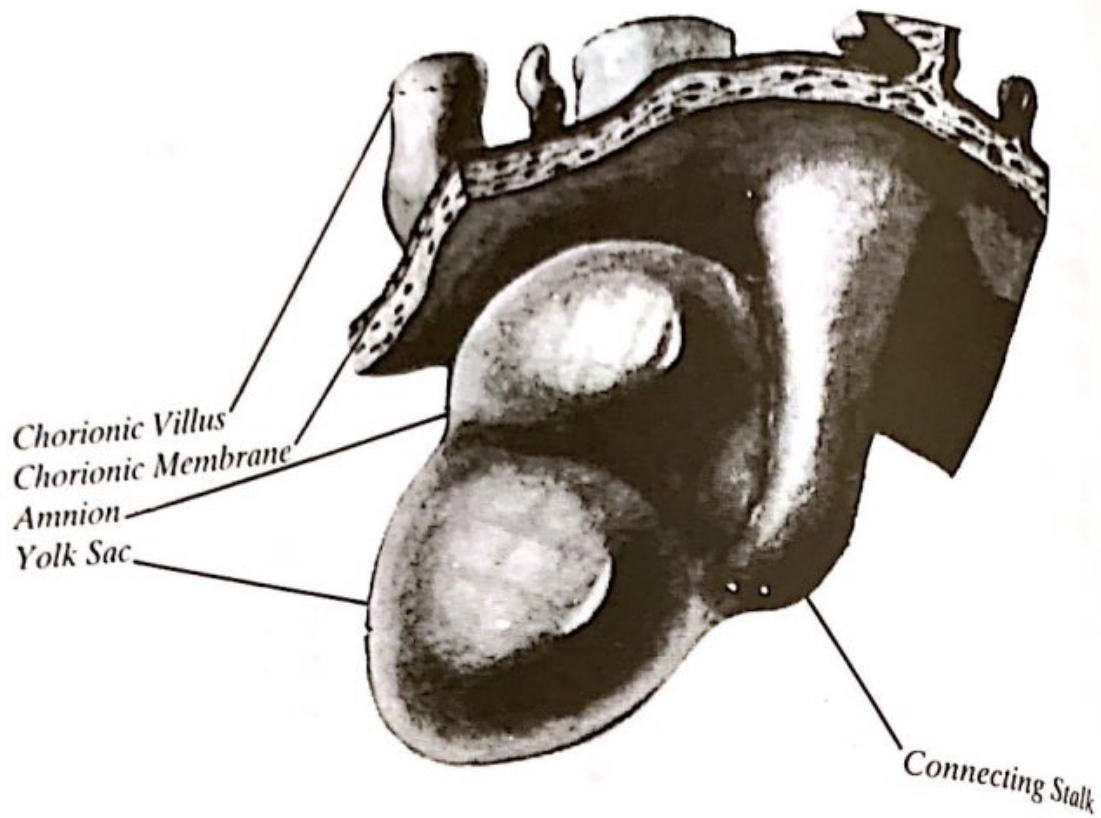


Fig. 37

A schematic representation of embryo with its amnion and yolk sac connected to the chorion with the Connecting Stalk. The chorion is anchored to the womb with Chorionic Villi.

REFERENCES

- (1) Ibn Hajar Al Asqalani: Fateh AlBary Shareh Sahih AlBokhary
Kitab AlQadar Vol. 11/481
AlMatbaa Assalafiyah, Cairo
- (2) Hamilton Boyd & Mossman: Human Embryology
4th Edition 1976
- (3) Medicine Digest 1981, Staniforth Webb/Foetal Clues to Preventing Rejection, June, P10-14
- (4) Keith Moore: The Developing Human P40 3rd Edition 1982 Saunders Company
- (5) a) AlJohary: AlSihah 3rd Edition 1983
b) Louis Maloof: AlMonjid 19th Edition
- (6) Textbooks of Embryology: Keith Moore: The Developing Human
Leslie Arey: Development Anatomy
Longman: Medical Embryology
Hamilton, Boyd and Mossman: Human Embryology.

THE MODGHA

The Modgha in Arabic means a chewed lump, something that has been masticated. Yousuf Ali in his translation of the Quran chose the word morsel of flesh which does not exactly translate the word Modgha. Mohammed Assad, Maurice Bucaille and others have chosen the correct translation i.e. a chewed like lump.

The word Modgha is mentioned twice in the Holy Quran, Sura 22/Verse 5 and Sura 23/Verse 14. In the Hadith (saying of the Prophet) it has been mentioned several times.

قال تعالى في سورة الحج ٥ / ٢٢
« يا أيها الناس إن كنتم في ريب من البعث فإننا خلقناكم من تراب ثم من نطفة
ثم من علقة ثم من مضغة مخلقة وغير مخلقة لنبين لكم . ونقر في الارحام ما
نشاء الى أجل مسمى ثم نخرجكم طفلا » .

Sura 22/5:

“O Man if you have doubt about Resurrection, consider that We created (every one of) you out of dust, then out of a drop of liquid (Nutfah), then from something that clings and adheres (Alakah) then from a chewed like lump (Modgha) which become differentiated into formed and non formed parts (Mokhalaga and non Mokhalaga). We rest whatever We want to the time We decide to bring you forth as babies”.

وقال تعالى في سورة المؤمنون ١٣ / ٢٣ « ولقد خلقنا الانسان من سلاله من
طين ثم جعلناه نطفة في قرار مكين . ثم خلقنا النطفة علقه فخلقنا العلقه
مضغه فخلقنا المضغه عظاما فكسونا العظاما لحما . ثم أنشأناه خلقاً آخر
فتبارك الله أحسن الخالقين »

Sura 23/13:

“We created man from the quintessence of mud, thereafter We placed him as a drop of liquid (sperm) in a firm lodging (the womb). Then We fashioned the sperm (Nutfah) into something that clings (Alakah) which

We fashioned into a chewed like lump (Modgha). The chewed like lump is fashioned into bones which are then covered with flesh. Then We developed it into another act of Creation. Blessed is God, the best to create."

The fertilized ovum multiplies into many small cells forming a ball like structure called the blastocyst. The inside of the ball is filled with a fluid. The blastocyst is formed of two layers:

- i) an external nourishing and clinging trophoblastic layer (trophe: nutrition)
- ii) an inner cell mass centrally located which gives rise to the embryo proper and its amnion and yolk sac.

The process of implantation is already discussed in the previous chapter, the Alakah. What is going inside the inner cell mass will be discussed here.

While the process of implantation is going on, the inner cell mass differentiates into 2 layers at the 8th day after fertilization, viz:

- a) a flattened cell layer forming the inner layer known as endoderm, and
- b) an outer layer of cubical cells forming the ectoderm.

Concurrently as the blastocyst is busy in implanting itself inside the uterine wall (7th to 12th day), the amniotic sac starts to form as a continuation of the ectoderm separating the inner cell mass from the cytotrophoblasts by a tiny space which enlarges gradually. Similarly, a continuation from the endoderm forms the proper yolk sac.

In the third week of embryonic life the bilaminar (2 layers) embryo is transformed into a trilaminar (3 layers) embryo. A primitive streak is formed on the surface of the ectoderm which ends cephalically (headwards) in a knot called the primitive knot or node.

The primitive streak is a very important hallmark in the developing embryo. It gives rise to a third layer of flattened cells that creep between the outer ectoderm and the inner endoderm, and completely separates the two layers except in three places: a) where the future mouth and heart will form (bucco-Pharyngeal membrane and Prochordal plate).

b) in the middle line where the primitive axis of the embryo forms the notochord.

c) at the tail end where the cloacal membrane forms where the external openings of the urethra and anus appear later on.

The primitive streak regresses rapidly after the 19th day and completely disappears at the end of the fourth week.

The notochord is the structure around which the vertebral column will grow. It also degenerates and disappears, only a part remains in the centre of the intervertebral discs which is called Nucleus Pulposus.

The notochord induces the overlaying ectoderm to form the neural tube from which the whole nervous system will grow.

Formation of Somites

The mesoderm on each side of the notochord and neural tube thickens to form a longitudinal column of paraxial mesoderm (i.e. thickened mesoderm near the axis) at the end of the third week. It soon breaks up into segmented blocks of epitheloid cells, called the Somites.

The first pair of Somites appear at the 19th to the 21st day at the cranial (headwards) end of the embryo. New Somites appear subsequently — 3 pairs of Somites daily. By the end of the fifth week, we find 42-44 pairs of Somites. These are 4 occipital, 8 cervical, 12 thoracic, 5 lumbar, 5 sacral and 8-10 coccygeal. The first occipital and the last 5-7 coccygeal disappear, the rest form the vertebral column and part of the base of the skull. (the 3 occipital fuse in the basiocciput).

The "Somites," as Hamilton Boyd and Mossman ⁽¹⁾ say "are conspicuous features of embryos in the period under consideration and are readily seen in the surface contour. They are the bases from which the greater part of the axial skeleton and musculature are developed."

The age of the embryo is expressed at this stage by the number of Somites since "they form one of its characteristic external features ⁽²⁾."

The Quranic term *Modgha* is even more acute than the term Somite period of development which is used in the texts of embryology.

The *Modgha* or "chewed like lump" with marks of indented teeth on it does not describe the Somites which are very conspicuous at this stage alone but includes the five pairs of pharyngeal arches which also appear at this period (4th week) as thickening and puckering of the mesoderm to fill the grooves formed by rapidly growing ectoderm and endoderm. Part of the face, ear and neck are formed from these pharyngeal arches.

The term "Somite period of development" does not include the pharyngeal arches which are important hallmarks at this stage.

The word "*Modgha*" is therefore a more precise descriptive term for this stage.

The Holy Quran divides the *Modgha* into *Mokhalaga* and non-*mokhalaga* i.e. differentiated and non differentiated.

It is amazing to find that the zenith of differentiation of the cells of the embryo occur at this stage "4th to 8th week."

This period is indeed very important, as each of the three germ layers gives rise to a number of specific tissues and organs.

"All the major organs and organ systems are formed during the fourth to the eighth week. This period is therefore, also called the period of organogenesis. It is the time when the embryo is most susceptible to factors interfering with development and most congenital malformations seen at birth find their origin during this critical period. (Langman. Medical Embryology.) (3)

The descriptive Quranic term Mokhalaga and non Mokhalaga is very astonishing indeed.

The Modgha "chewed like lump" is described to differentiate into formed and non formed parts. The Quranic verse says:

We created you out of dust, then out of a drop of liquid (Nutfah), then from something that clings (Alakah), then from a chewed like lump (Modgha) which becomes differentiated into formed and non-formed parts. We rest whatever We want to the time We decide to bring you forth as babies."

The Prophet Mohammad (peace be upon him) said: "When 42 days pass after the Nutfah settles in the womb, God sends an angel to shape it and create its hearing, its vision, its skin, its flesh and bones, and then the angel says: "O God, Is it a boy or a girl?" and God dictates whatever He wants." Narrated by Muslim.

Another Hadith, narrated by both Bokhari and Muslim (the most authentic books of the sayings and deeds of the Prophet) states that an angel follows the drop of semen (Nutfah) from the time it enters the womb till it is completed or aborted.

It is well known that this period (6th week) sees the zenith of organogenesis whereby hearing system, visual system, bones, flesh and skin are laid down. This is rapidly followed by the differentiation of the gonads into testes or ovaries, as the Hadith proclaims.

It is indeed very revealing to grasp all these embryological data that has been expounded in the Holy Quran and sayings of the Prophet (peace be upon him.)

Only recently it was known that the gonads start to differentiate into testes or ovaries at the 7th — 8th week of intra uterine life.

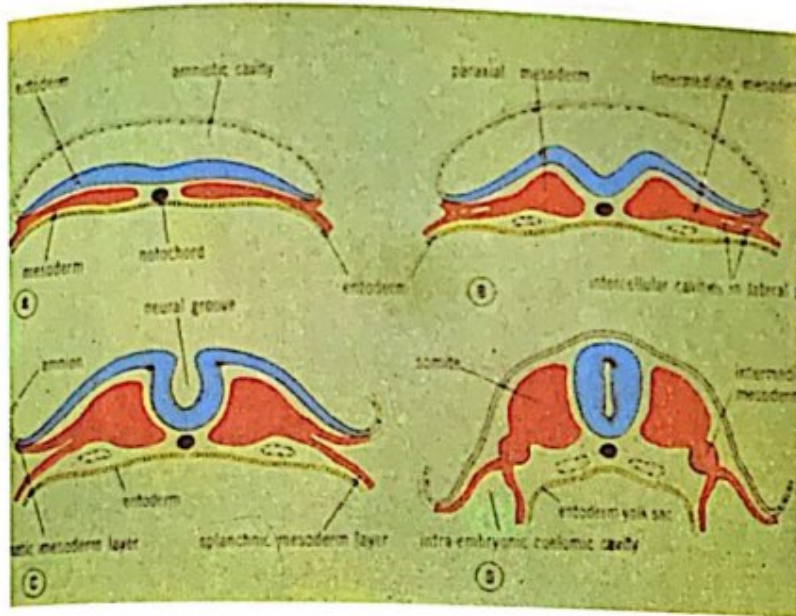


Fig. 38
 Transverse sections showing the development of the mesoderm and the formation of the Somites from the paraxial mesoderm.

A is 17 day embryo, B 19 day, C 20 day, D 21 day. The Somites give the embryo a characteristic shape similar to a chewed lump "Modgha."

The Somites are the most conspicuous parts of the embryo at this stage and the age of the embryo is expressed by the number of Somites (at this stage).

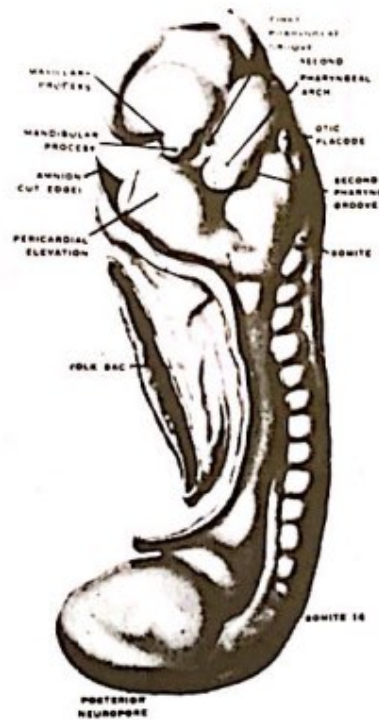


Fig. 39
 A 14 Somite embryo of about 25 days. The Somites and the Pharyngeal arches give this embryo the look of a masticated lump, whereby the indentations of the teeth are apparent. The Quranic word Modgha precisely describes this feature. Further "the Modgha" is fashioned into bones that are clothed by flesh." The Somites are in fact transformed into Sclerotome which forms the skeleton of the embryo and myotome which gives rise to the muscles that cover the bones.

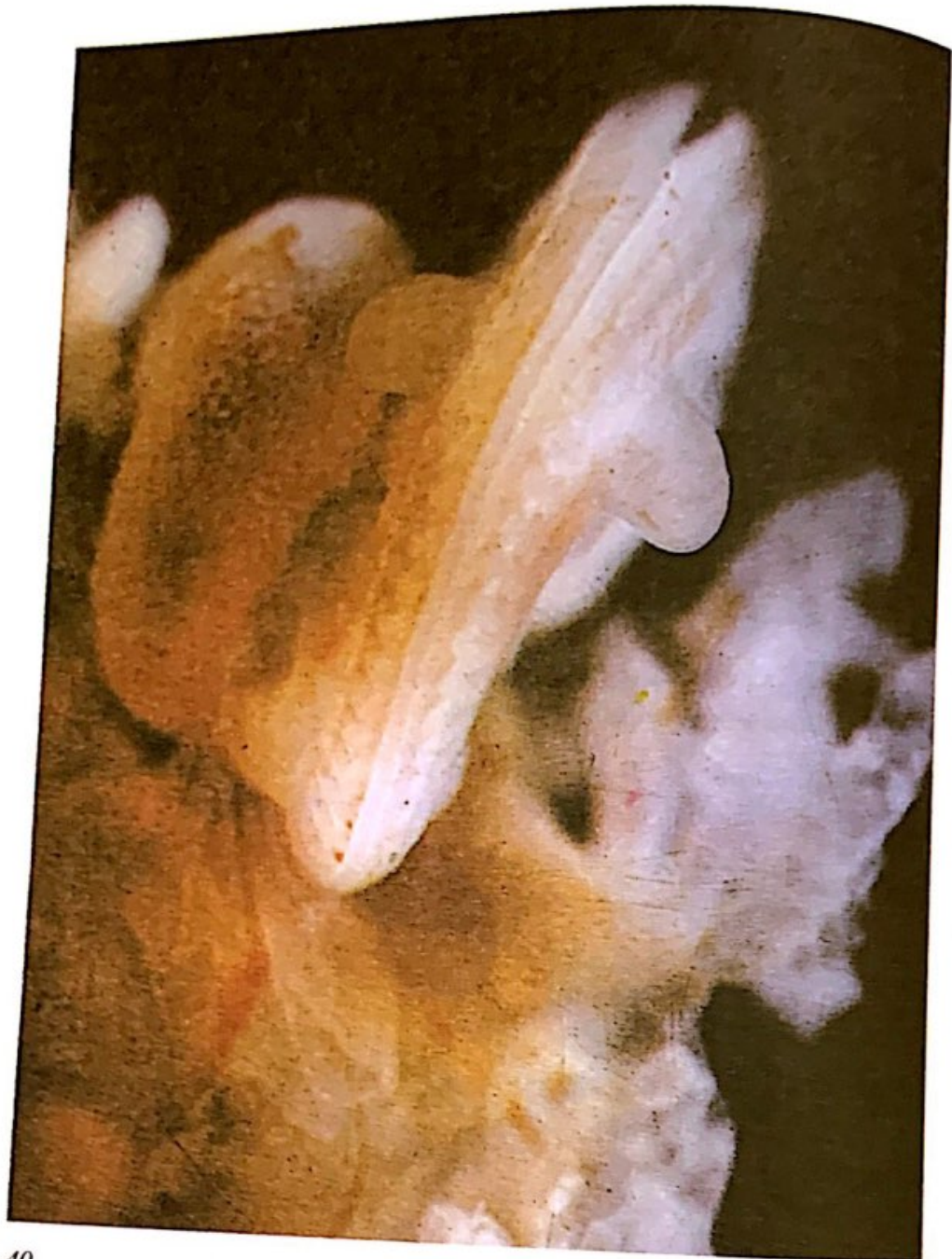

Fig. 40

At 4 weeks, the embryo is at the stage of "Somite period". The Somites are clearly seen in this 6mm embryo, where the neural groove is almost closed completely except at the tip where a cleft is seen. The paraxial mesoderm has thickened to form the beaded and segmented appearance. Soon it will form the bodies and arches of the vertebrae and will enclose the neural tube. The muscles will then clothe the vertebral bodies.

The Quran describes this phenomenon by the word Modgha which means a chewed like lump — this Modgha is fashioned into bones that are clothed with muscles.

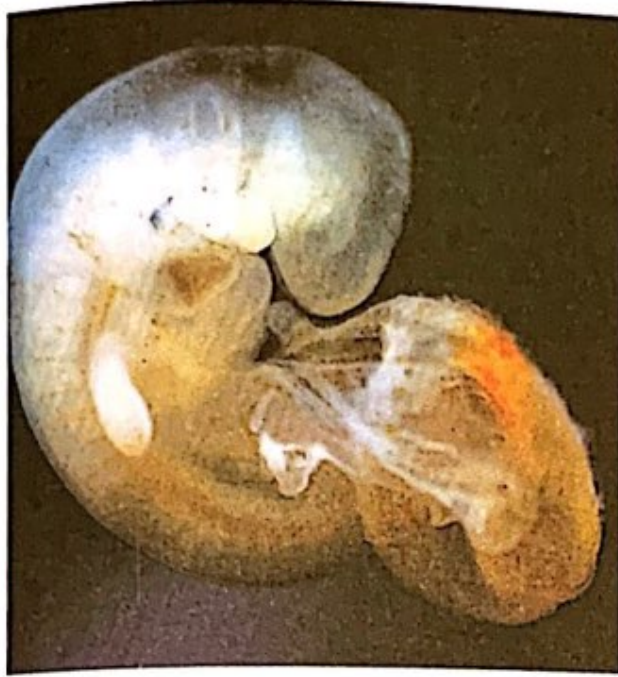

Fig. 41
At the end of 4 weeks, 7 mm embryo, the Somites are evident at the trunk as a beaded segmented column. The head is still with unhuman features with Pharyngeal arches. The heart is literally at its mouth. The limb bud has started protruding from the side.

There is no better term for this embryo than the word "Modgha" used by the Holy Quran.

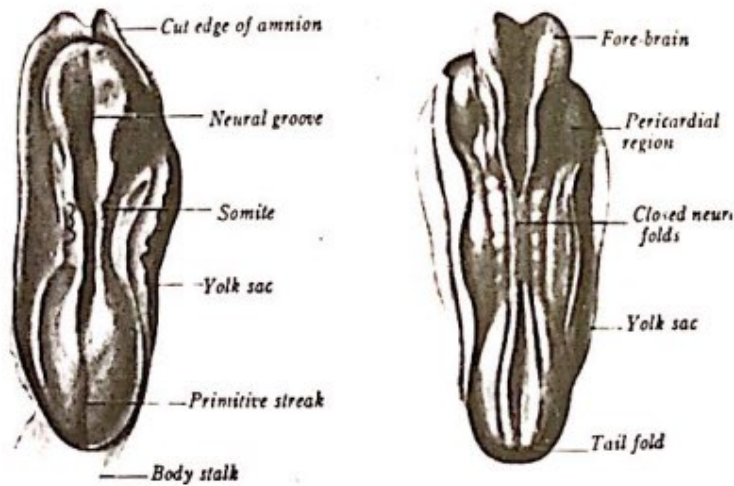


Fig. 42

A. An embryo 20 days old where the first pair of Somites appear. The neural groove is not yet closed, and the primitive streak is still apparent.

B. 14 pairs of Somites have already developed in this embryo. The neural groove started closing. The developing Somites will soon form the Sclerotomes, from which the vertebrae will be established.

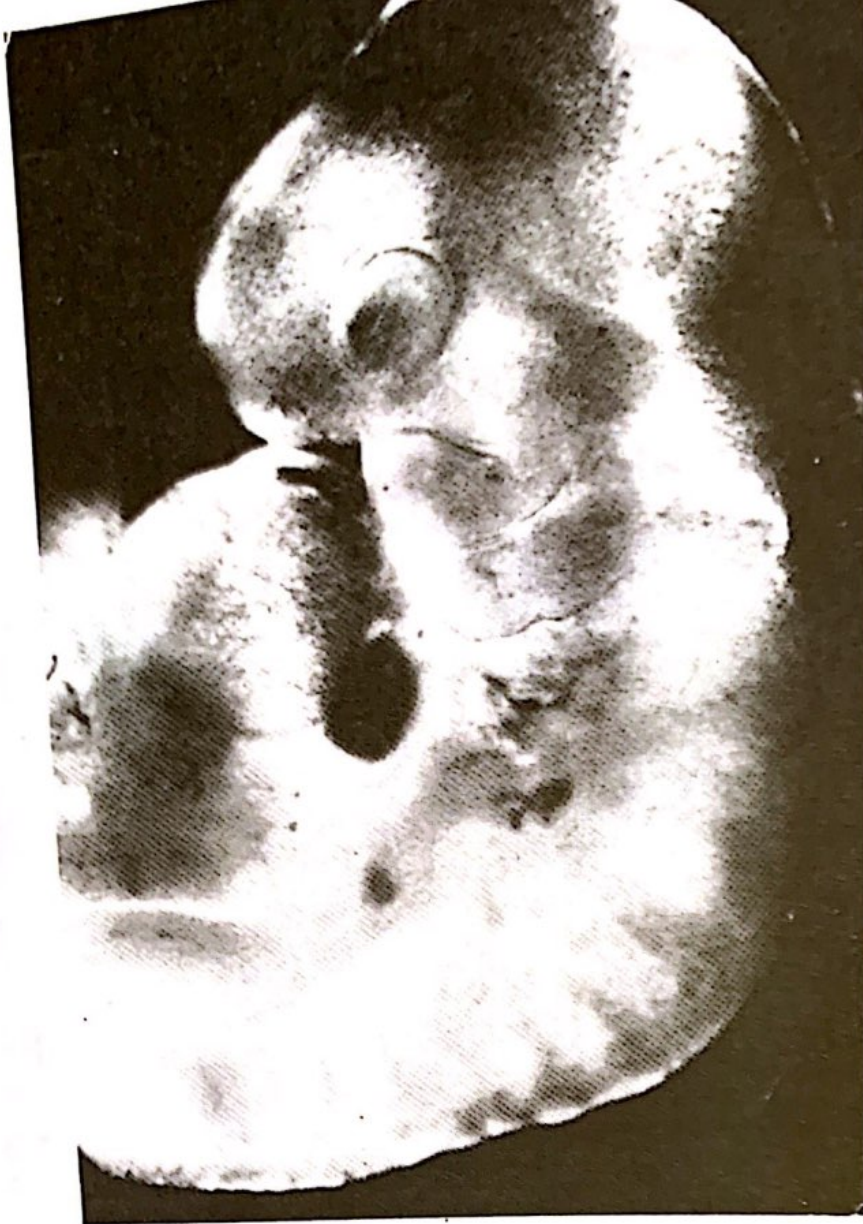

Fig. 43
At 30 days (6-7mm). The bizarre look of this embryo is in great variance to the human face that would appear after three to four weeks.

The Pharyngeal arches and the Somites are giving the embryo the shape of a "chewed lump" or Modgha.

God has fashioned you in whatever form He wills.

REFERENCES

- 1 & 2: Hamilton, Boyd and Mossman: Human Embryology 4th Edition 1976 P.178
3. Langman, Jan, Medical Embryology, 3rd Edition, 1975.

Bone and Flesh Formation

قال تعالى :

« فخلقنا العلقة مضغة فخلقنا المضغة عظاما فكسونا العظام لحما »
سورة المؤمنون ١٢/٢٣

Sura 23/13

The chewed lump "Modgha" is fashioned into bones which are clothed with flesh.

"The Somites are the bases from which the greater part of the axial skeleton and musculature develop" as Hamilton, Boyd and Mossman say.⁽¹⁾

The truth and preciseness of the Quranic verse is really breathtaking.

The chewed lump "Modgha" or Somite Embryo develops into the skeletal system which is covered by muscles.

The Somites early in the fourth week begin to differentiate, whereby the ventromedial mass of cells of the somite show high proliferative activity. The mesenchymal cells differentiate into fibroblasts, (precursors of fibres), chondroblasts (precursors of cartilage) or Osteoblasts (precursors of bone).

These cells migrate towards the axis where the notochord and neural tube are formed.

This part of the Somite is known as the sclerotome. The vertebral column is formed by cells of the sclerotome migrating in front of the notochord and neural tube. The neural tube is later enclosed by the arches from the vertebral bodies, while the notochord regresses and disappears. The remnant of the notochord is found in the centre of the intervertebral discs in the form of the nucleus pulposus.

The remaining cells of the somite that were not used in forming the Sclerotome soon differentiate to form the myotome, which provide the muscles that enwrap the developing bones.

Thus we find the Sclerotome "the precursor of bones" laid down first, followed immediately by the myotome "the precursor of muscles." The latter is covered by the precursor of skin, the dermatome.

The Quran declares that bone formation precedes muscles. Once the bones are laid down they are covered by muscles.

We find this both in the vertebral column and in the limb bones.

The fore limb bud appears at 5th week, while the lower limb bud appears at sixth week.

Each bud is made up of mesenchymal (undifferentiated) cells from the corresponding somite along with a covering of ectoderm.

The upper limb is made from cervical somites 5-8, and 1st thoracic somite; the lower limb from the lumbar somites (1-5) and the upper two sacral somites.

The apex of the bud is thickened forming a ridge which induces the underlying mesenchyme to grow and differentiate. Some mesenchymal cells differentiate into chondroblasts whereby the first hyaline cartilage model of bone is formed at the sixth week.

Langman states ⁽¹⁾ "The first indication of the limb musculature is found in the seventh week of development as a condensation of mesenchyme (from the Somites) near the base of the buds. In the human embryo this mesenchyme is derived from the somatic mesoderm."

"With elongation of the limb buds, the muscular tissues, as yet undifferentiated splits into flexor and extensor components."

This clearly indicates that cartilage model precedes the formation of the primitive muscles. Once the cartilage model is formed, it is enveloped by the muscles differentiating from the surrounding mesenchyme.

It is breathtaking to read this Quranic verse.

« فخلقنا المضغة عظاما فكسونا العظام لحما »

"The chewed lump is fashioned into bones which are then clothed with flesh."

The precision of this description is not excelled in its beauty, simplicity and accuracy.

In another verse, we read:

« فانظر الى العظام كيف ننشزها ثم نكسوها لحما » البقرة ٢٥٩

Sura 2/259

"And look at the bones how We erect them, then We enclothe them with flesh". Another translation goes like this: "Look at the bones how We bring them together and clothe them with flesh."

The word "Nan Shuzuha" literally means: erect it, or make it prominent or conspicuous. The other reading "Nan Shuruha" means put life again in it.

Langman describes bone formation as follows: "With time a number of needle like bone spicules are formed which progressively radiate from the primary ossification centres towards the periphery.

The word "Nan Shuzuha" says what Langman has expressed in the above quotation.

Such is the beauty and accuracy of the Quranic descriptive terms. There is no comparable term in the human language, let alone one that can excel it.

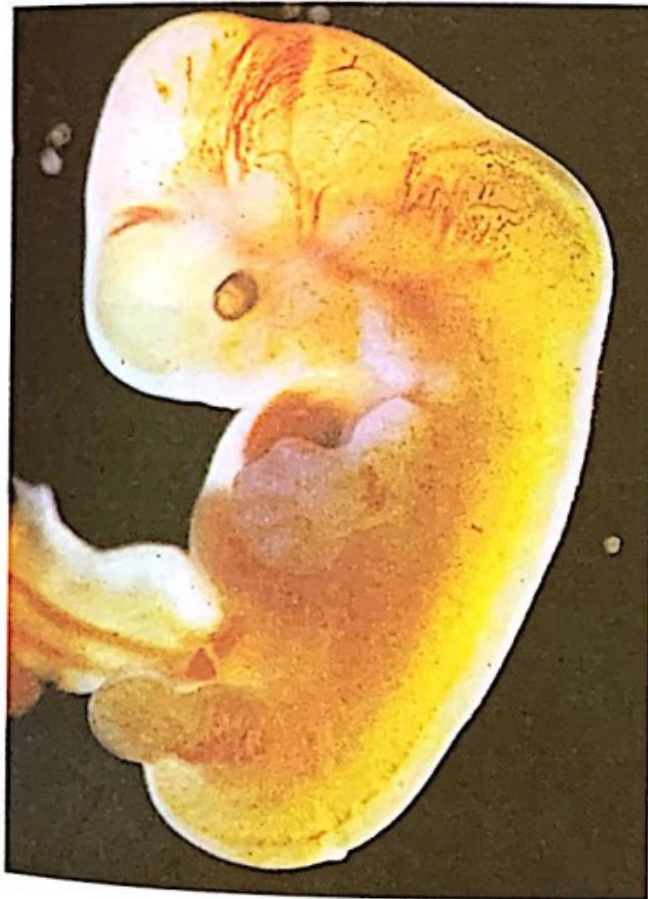


Fig. 44
At the end of Fifth week (11-12mm), the Somite stage embryo has been converted into the primary hyaline cartilaginous skeleton. The upper limb already shows the faint fingers.

The Quranic verse reads as follows:
The "Modgha" chewed like lump is fashioned into bones which are clothed with flesh.




Fig. 45
The skull of the 7th week, where blood vessels creep to lay down Spicules of bone directly on a thin membrane. This is the only site in the body where bone formation is not preceded by cartilage model.

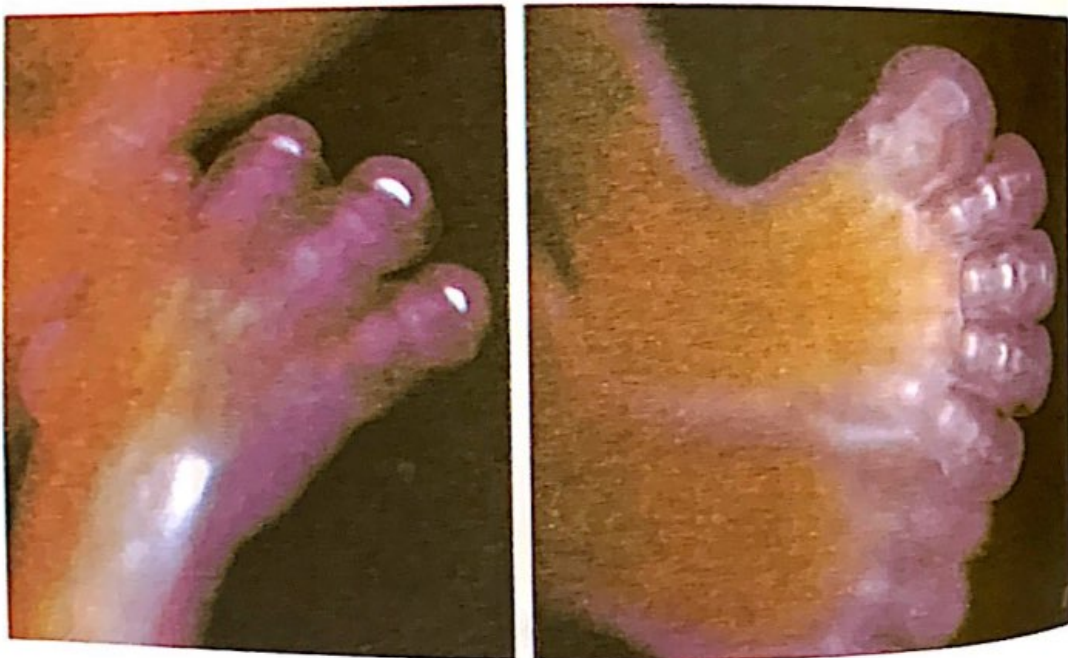

Fig. 46
A hand and foot of an embryo aged 8 weeks. The cartilaginous model of fingers and toes are conspicuous. The joints of fingers and toes are showed distinctly.

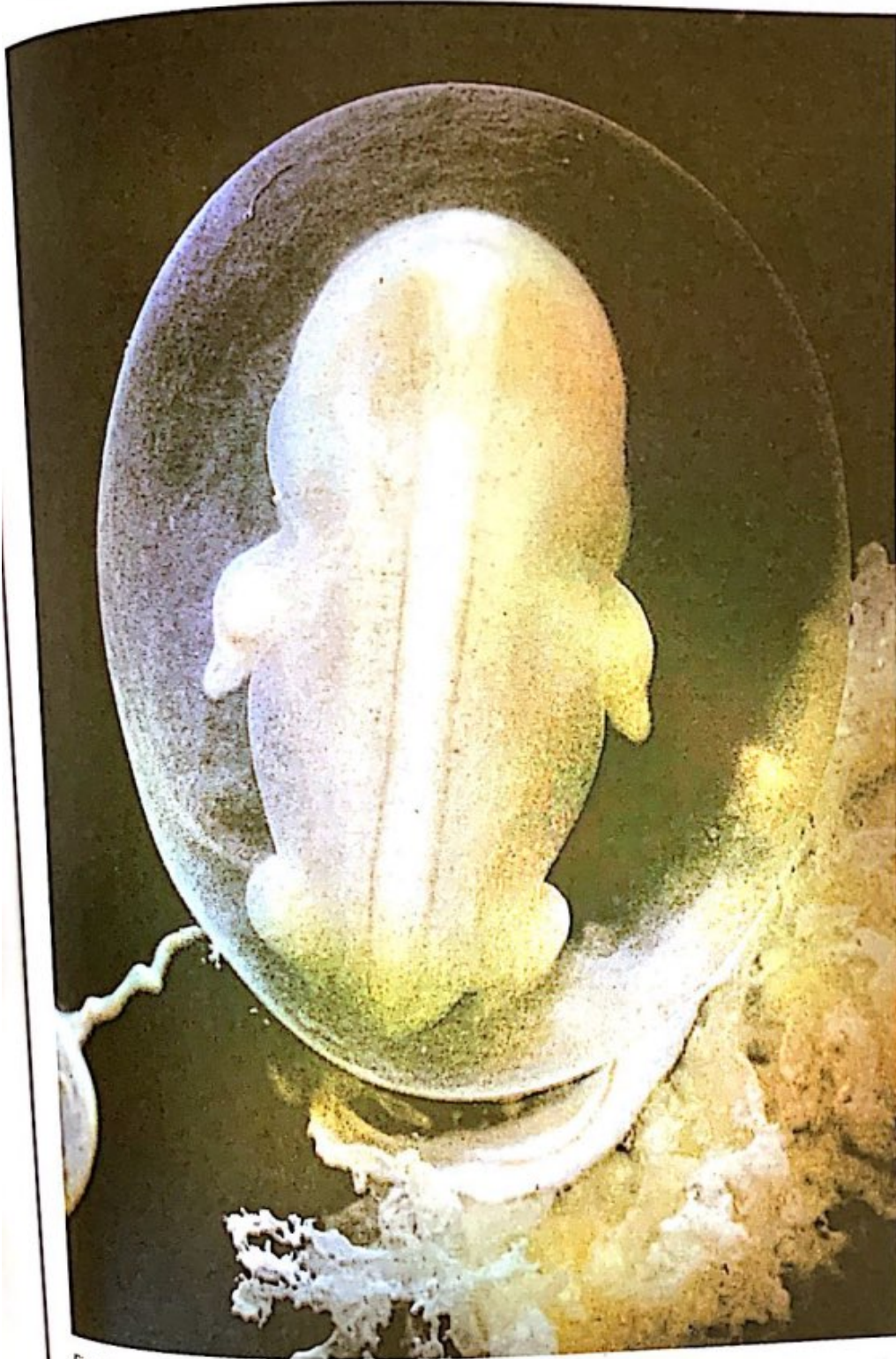


Fig. 47
An embryo 6 weeks old (1.5 mm long). The embryo floats in the amniotic fluid quite freely. The limb buds are apparent, and the early vertebral column is delineated by blood vessels that run on each side of it. (Paravertebral arteries).




Fig. 48
This embryo is only 6 weeks old (1.5 cm). The blood vessels are seen shimmering through the thin membranous skull. The upper limb buds are seen clearly with fingers demarcated. The heart lies just below the chin.

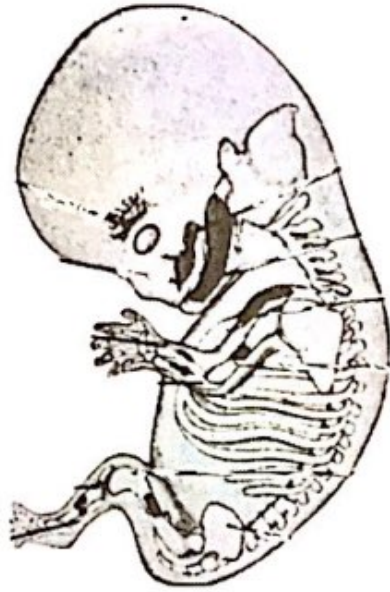

Fig. 49
8 weeks embryo where primary centres of ossification appear in the cartilaginous skeleton.

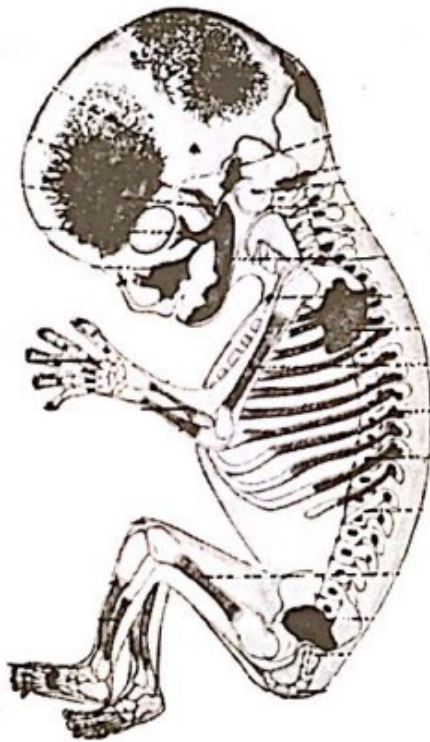


Fig. 50
A 10 weeks embryo wherein ossification spreads throughout the skeleton including the vault of the skull, where ossification is not preceded by cartilage models unlike found in most parts of the skeleton.

The Sex of the Embryo

There are three levels which determine the sex of human beings.

First: At the genetic level. This is determined very early at the time of fertilization when the male gamete unites with the female gamete. It is the male gamete, viz. the sperm, which determines the genetic sex of the future embryo. If the sperm which fertilizes the ovum is carrying a Y chromosome, the offspring will be a boy, while if it is carrying an X chromosome it will be a girl (by the Will of God).

The Holy Quran succinctly described these facts, which were only known scientifically in the twentieth century.

قال تعالى : « وانه خلق الزوجين الذكر والأنثى من نطفة اذا تمنى »
النجم ٤٥-٤٦

Sura 53/45-46:

“God fashioned both male and female from a drop of fluid (sperm) that has been ejaculated.”

وقال تعالى : « أبحسب الانسان أن يترك سدى . ألم يك نطفة من منى يمنى
ثم كان علقة فخلق فسوى فجعل منه الزوجين الذكر والأنثى . اليس ذلك
بقادر على أن يحيي الموتى » القيامة ٣٦-٤٠

Sura 75/39:

And He out of semen made both sexes, the male and female.”

Scientists can now identify the male sperm (i.e. carrying Y Chromosome) from female sperm (i.e. carrying an X Chromosome) by means of fluorescent material which attaches itself to the Y Chromosome only. Under the ultra violet light the Y carrying sperms fluoresce and gleam as shown in the following pictures.

Second: Gonadal Sex. This is determined at the seventh and eighth week when the genital ridges, become invaded by germ cells forming the primitive sex cords proliferating and differentiating into either the ovaries or testes. The sex of an aborted fetus at six weeks cannot be determined by histological examination of the gonads. (1)

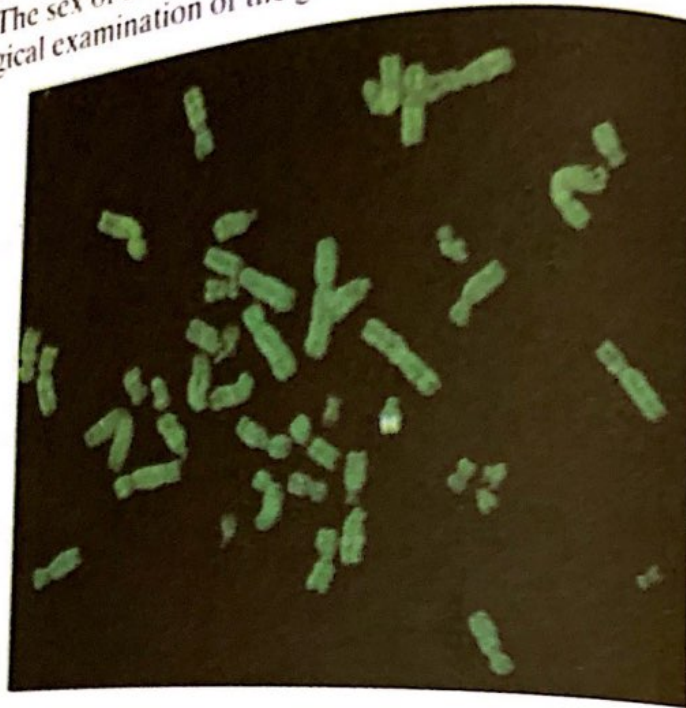


Fig. 51
A dividing human cell (above) has been flattened out gently so that the chromosomes have floated apart. They have been treated with a substance causing certain parts of them to emit light under ultraviolet rays. Each type of chromosome has its own "pattern." The tiny short-armed Y chromosome (centre) emits a particularly strong light.

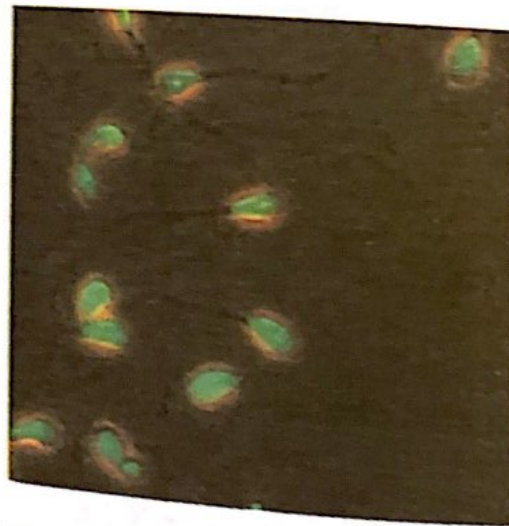


Fig. 52
In sperm (left) treated the same way as the chromosomes in the photo above, a small gleaming spot is visible in the "boys." This is the Y chromosome.
(From "A child is Born" by Lennart Nilsson)

THE ORIGIN AND TIME OF FORMATION OF THE GONADS

قال تعالى : « فليُنظر الانسان مم خلق . خلق من ماء دافق يخرج من بين الصلب والترائب . انه على رجعه لقادر يوم تبلى السرائر »

الطارق ٥-٩

Sura 86/5-9:

"Let Man then observe out of what he has been created; he has been created out of gushing water (ejaculated fluid), which comes out from between the vertebral column and the ribs. He (God) can get him back to life on the Day when all secrets will be laid bare."

وأخرج الامام مسلم (كتاب القدر) عن حذيفة ابن اسيد رضى الله عنه قوله صلى الله عليه وسلم : « اذا مر بالنطفة ثنتان وأربعون ليلة بعث الله ملكا فصورها وخلق سمعها وبصرها وجلدها ولحمها وعظامها ثم قال يا رب اذكر أم أنثى فيقضى ربك ما شاء ويكتب الملك »

The Prophet Mohammad (peace be upon him) said: "When the Nutfa enters the womb and stays there forty nights, God sends an angel to give it its form and creates its hearing, visual apparatus, skin, bone and flesh. Then he asks: O God, is it a boy or a girl? and God determines whatever He decides." Narrated by Muslim (Kitab Al Qadar).

The above mentioned Quranic Ayas (verse) states clearly the site of formation of human gonads. The commentators of the Holy Quran differed in their explanation of this aya into two main groups. The first group includes the majority of the old commentators like Ibn Jarir AlTabri⁽²⁾ Ibn Kathir⁽³⁾, Tafsir AlGalalain⁽⁴⁾ who understood that the semen (male secretion) comes from the bones of the back and the female part comes from the ribs. The minority of commentators like Ibn Al Qaim⁽⁵⁾, Al Qortobi⁽⁶⁾, Al Oloosi⁽⁷⁾ said that the Quranic ayas are clear in indicating that both the male and female sexual gonads come from a place in between the bones of the back and the ribs i.e. loins.

Al Qortobi quoted Al Hasan Al Basri who lived in the first century Hijra (7th century A.D.) as taking sides with the second view.

In recent times Al Maraghy⁽⁹⁾ took the advantage of supporting the second view, by the advances of science in the field of anatomy and embryology.

Al Maraghy, though he was the Sheikh of Al Azhar, grasped well the scientific data and presented them succinctly in his Tafsir.

Syed Qotob⁽¹⁰⁾ in his Tafsir "Fi Dilal Al Quran" who came thirty years later, could not grasp the scientific facts and made a lot of mistakes in this point.

It is well known, now, that the gonads appear in the region of the future loins. The genital ridges make their first appearance in a 4 week embryo on each side of the midline between the mesonephros and the dorsal mesentery. "Germ cells do not appear in the genital ridges until the sixth week of development"⁽¹¹⁾.

This point is quite important as the Prophet Mohammad (peace be upon him) stated in the Hadith narrated by Muslim (already quoted) that the angel is ordered to fashion the sex of the embryo at 40 — 42 days.

Langman⁽¹²⁾ states: "In the sixth week of development the Primordial germ cells invade the genital ridges, if they fail to reach the ridges, the gonads do not develop and gonadal dysgenesis is a well known Syndrome in the female."

The gonads once formed become differentiated into male and female gonads by the seventh and eighth weeks.

The gonads then start a process of descent, the female gonads (the Ovaries) stop in the true pelvis, while the male gonads continue their descent before birth to reach the Scrotum outside the body through the inguinal canal.

However, the nerve supply, the blood supply and the lymph drainage remain even in the adult connected to the area cited in the Holy Quran as between the vertebral column and the ribs. The testicular arteries come from the abdominal aorta at the level of second lumbar vertebra. The right testicular vein drains into the inferior vena cava, while the left drains into the left renal vein.

The anatomical and embryological data greatly help in understanding the Quranic ayas and the sayings of the Prophet. It is also quite revealing to find the Holy Quran and the Hadith of the Prophet (peace be upon him) mention such an accurate statement of what goes on inside the wombs in a very early stage of development. These facts were never known by the scientists except in the twentieth century.

The Third: THE FORMATION OF THE EXTERNAL GENITALIA.

The embryo passes into an indifferent stage, both in the gonads and the external genitalia. The indifferent gonads form at the sixth week, but soon become differentiated into male gonads (testes) or female gonads (ovaries) at the eighth week.

The external genitalia also pass into an indifferent stage. Early in the third week the genital tubercle forms as a result of union of mesodermal folds at the site of the Cloaca.

At the sixth week the Cloaca is subdivided by a septum into two parts: the urogenital and anal membranes. Meanwhile genital swellings become visible on each side of the urethral folds.

By the end of the sixth week the external genitalia of both male and female are identical and it is impossible to distinguish between the two sexes. ⁽¹¹⁾

This again emphasises the importance of the Hadith of the Prophet Mohammad (peace be upon him) which was narrated by Muslim and already quoted, whereby the angel enters the womb at 40th — 42nd day and asks "O God, is it a boy or a girl, and God determines whatever He decides."

The differentiation of the external genitalia starts after the sixth week. It goes on slowly so that by the twelfth week it becomes relatively easy to recognise the male from the female.

To sum up it is astonishing to find the Holy Quran and the Hadith of Prophet Mohammad (peace be upon him) have described succinctly these three levels of sex determination i.e.

- the genetic level
- the gonadal level
- the external genitalia level

Certainly the study of these Quranic verses and the sayings of the Prophet (peace be upon him), in the light of scientific knowledge of twentieth century, give a better understanding for these scriptures. It is also clear that such pristine knowledge which was revealed fourteen centuries ago, was beyond the capacity of any mortal to grasp at that era.

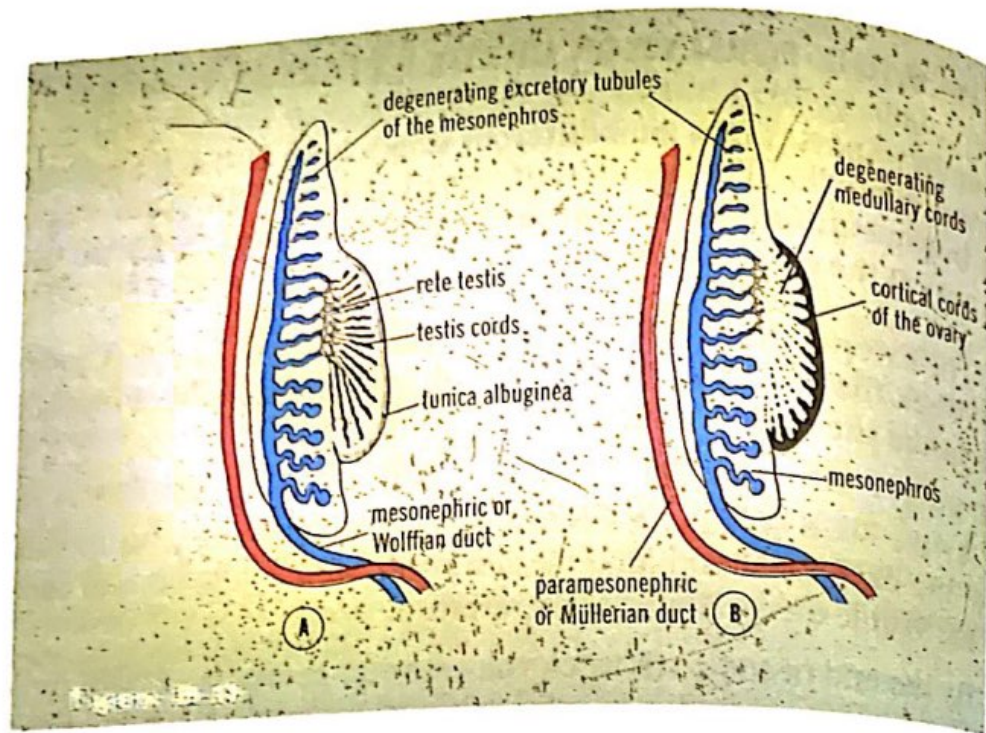


Fig. 53
 Diagram of the genital ducts in the sixth week of development in male A and female B. It is difficult to differentiate the two sexes.

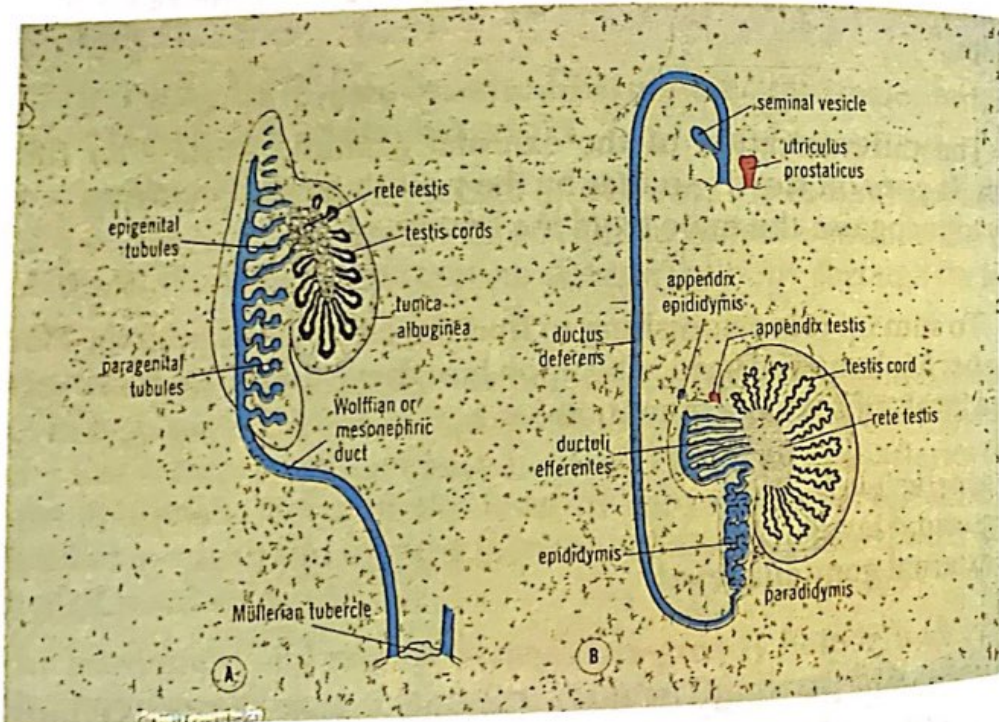


Fig. 54
 (A) Diagram of the genital ducts in the male in the 4th month of development.
 (B) The genital duct after descent of testes.
 (Diagrams from Langman's Medical Embryology)

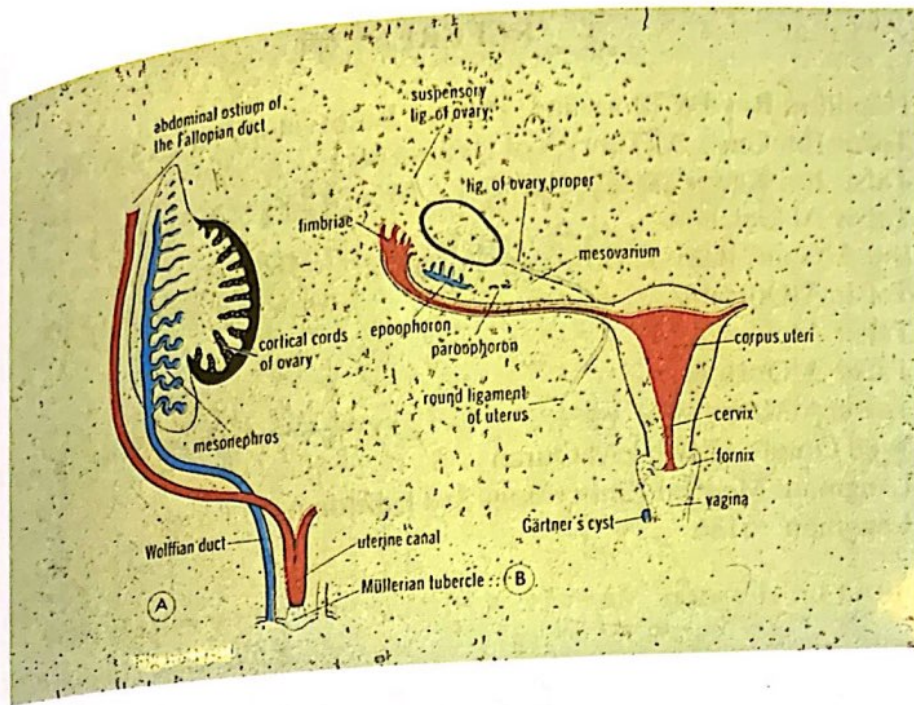


Fig. 55

Fig. A

Diagram of the gonad and genital ducts in the female at the end of 8th week. The gonad is already differentiated into ovary. The uterine canal is starting to form.

Fig. B

The ovary has already descended down to the pelvis, the uterus is well formed by the union of the distal portion of the Mullerian duct. The proximal and middle portions form the uterine tube "the Fallopian tube" one on each side of the uterus.

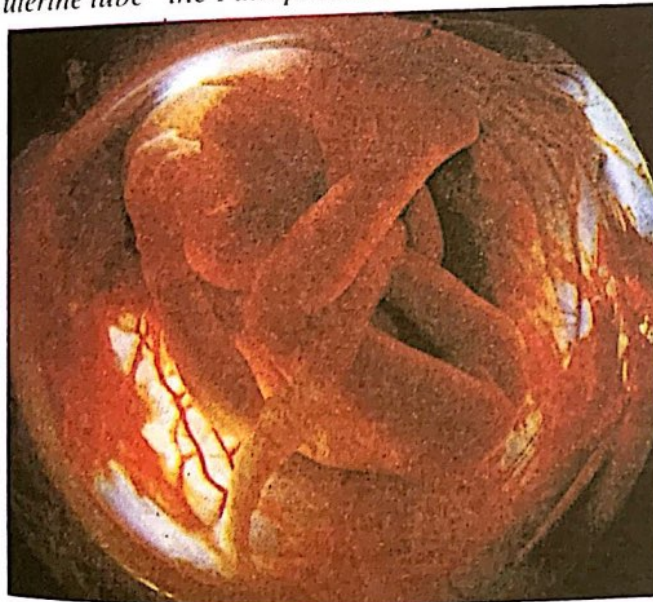


Fig. 56

A female fetus, just over 5 months old, was photographed while still in untero (in the womb) by Lennart-Nilsson (From his book *a Child is Born*).

REFERENCES

- 1) Hamilton Boyd & Mossman: Human Embryology Pages 338, 400
- 2) Tafsir Ibn Gasir Al Tabry Vol 30/Sura 86
- 3) Tafsir Ibn Kathir Al Dimshqy
- 4) Tafsir Al Galalain
- 5) Ibn AlGain: Ilam AlMowoqin Vol I/158
- 6) Tafsir AlQortabi
- 7) Tafsir Aloloosi
- 8) Tafsir AlQortobi
- 9) Tafsir AlMaraghy
- 10) Syed Qotab: Fi Dilal Al Quran
- 11) Langman: Medical Embryology 3rd Edition p. 175
- 12) Langman: "/186

GIVING THE SHAPE AND FORM (formation of the face)

قال تعالى : « هو الذي يصوركم في الأرحام كيف يشاء لا اله الا هو العزيز الحكيم » آل عمران ٦

Sura 3/6:

“He it is Who shapes you in the wombs as He will. There is no God but He, the Almighty, the Wise.”

وقال تعالى : « ولقد خلقناكم ثم صورناكم » الاعراف ١١

Sura 7/11:

“We have created you and then formed you.”

وقال تعالى : « وصوركم فأحسن صوركم ورزقكم من الطيبات » غافر ٦٤

Sura 40/64:

“And He has given shape, and made your shapes beautiful, and has provided for you sustenance.”

وقال تعالى : « يا أيها الانسان ما غرك بربك الكريم - الذي خلقك فسواك فعدلك في أي صورة ما شاء ركبك » . الانفطار ٦-٨

Sura 82/6-8:

“O man! What has seduced thee from thy Lord Most Beneficent? — He who created thee, and fashioned thee in due proportion, and gave thee a just bias. In whatever form He wills, does He put thee together.”

وقال تعالى : « هو الله الخالق البارئ المصور . له الأسماء الحسنی »

الحشر ٢٤

Sura 59/24:

“He is God, the Creator, the Evolver, the Bestower of forms. To Him belong the most Beautiful names.”

The shaping and reshaping of the embryo and fetus while still in the womb of his mother is a continuous dynamic process.

قال تعالى : « يخلقكم في بطون أمهاتكم خلقا من بعد خلق في ظلمات ثلاث »
الزمر ٦

Sura 39/6:

“He creates you in your mother’s wombs, one act of creation after another, in three veils of darkness.”

As man is created in successive stages starting from Nutfa, Alakah, Modgha, bone formation, muscles covering the bones... and then into another act of creation; it is evident from the Quranic verses that shaping and remodelling of this creature is a constant and incessant process.

قال تعالى : « مالكم لا ترجون لله وقارا . وقد خلقكم أطوارا » .

Sura 71/13-14:

“What is amiss with you that you cannot look forward to God’s Majesty. He has created everyone of you in successive stages.”

The Nutfah, Alakah, Modgha, Bone and Muscle formation were already discussed in the previous chapters.

In a three week embryo, three germ layers are already recognised and the embryo is trilaminar.

The outer layer is the ectoderm.

The inner layer is the entoderm.

And the middle layer is the mesoderm.

Each of these three layers participates in the formation of different organs and systems.

The outer layer ectoderm: Forms the brain, spinal cord and nerves (the Nervous System), the epidermis of the skin with hair, sebacious glands and Sweat glands. The epithelium of the upper and lower end of the alimentary canal (i.e. the mouth, lips and palate and the anal canal) are derived from the ectoderm. Similarly, most parts of the eyes are derived from the ectoderm (the cornea, lens, iris and retina).

The entoderm (inner layers) mainly form the epithelium of the alimentary tract except its terminal parts (mouth and anus). It also forms the liver, the pancreas, the parathyroid and the thymus glands.

Similarly, the respiratory tract epithelium is derived from the entoderm.

The epithelium of the bladder, part of the urethra and part of the vagina are also derived from the entoderm.

The mesoderm (the middle layer) forms the whole connective tissue including the bones, cartilages, muscles, kidneys and ureters, the heart and blood vessels and most of the genital organs. The dermis of the skin is also derived from this layer.

By the end of the third week the primitive heart starts to beat and will continue until cessation of life.

During the fourth week, the somites develop on each side of the neural tube. Forty or more such pairs of somites form. The first four somites unite to form part of the base of the skull, the basiocciput, the second and eight somites form the cervical vertebrae followed by 12 thoracic vertebrae, which are followed by 5 lumbar, 5 sacral and 8-10 coccygeal which later disappear except three or four.

From the cervical region (5-8) comes the limb buds, while from the thoracic region, twelve ribs appear.

From the lumbar (2-5) and sacral (1-2), the lower limb buds make their appearance.

Between the vertebra, nerve stems are growing from the developing spinal cord.

The primordial muscles form as soon as the primordial bones form. They are derived from the somites which form the vertebral column, and give the embryo its beaded appearance.

Between the primitive mouth and the heart, the future face begins to take shape.

At the end of the fourth week an ectodermal depression known as the Stomodeum (or the primitive mouth) become surrounded by the first pair of pharyngeal arches. These arches are due to aggregation of mesodermal masses on each side of the future neck.

They are covered by ectoderm from outside and entoderm from inside. There are six pairs of these arches. The fifth pair degenerates early.

The first (or mandibular arch) consists of two portions:

- a) a Cephalic one, the maxillary process
- b) a Caudal one, the mandibular process

Both participate in formation of the face, and the small bones of the middle ear (incus and malleus).

The second arch forms part of the hyoid bone (tongue bone).

The third arch, forms the rest of it.

The fourth and sixth arches fuse to form the cartilages of the larynx (i.e. thyroid and cricoid cartilages.)

The face is formed by five elevations (tubercles) of the mesoderm, at the fifth week:

Two mandibular swellings (from mandibular process of first arch) and two maxillary swellings (from maxillary process of the first arch) and one central frontal prominence.

Two fast growing ridges, the lateral and medial nasal swellings, then appear. The lateral swellings will form the alae of the nose, while the medial swellings will give rise to:

- 1) the middle portion of the nose
- 2) the middle portion of the lip
- 3) the middle portion of the maxilla
- and 4) the primary palate.

During the sixth and seventh week the appearance of the face changes considerably. The maxillary swellings grow medially, thus compressing the medial nasal swellings toward the midline, and ending in their fusion. The upper lip is thus formed.⁽¹⁾

The cheeks develop by positional changes of the tongue, the floor of the mouth and broadening of the mandible.⁽²⁾

The cheeks and lips are then invaded by mesenchyme of the second pharyngeal arch giving rise to the muscles of the cheeks and lips.⁽³⁾

By a complex process the maxillary swellings unite with the lateral nasal swellings.

The union of medial nasal swellings form:

- 1) centre (philtrum) of the upper lip
- 2) part of the primary palate
- 3) part of the jaw which carries the 4 incisor teeth.

The main part of the definitive (secondary) palate come from the maxillary swellings — during the seventh week of embryonic life.

The nasal chambers appear from the nasal swellings at the sixth and seventh week.

Any disturbance of growth at this period results in many congenital malformations ranging from the simple hare lip to the more complex cleft palate.

The development of the tongue starts at the fifth week as a protuberance in the middle of the pharynx, which soon unites with similar swellings formed by the first Pharyngeal arch.

The base of the tongue forms from a swelling from the second Pharyngeal arch. The muscles of the tongue come from the occipital somites which also form the basiocciput of the skull. This explains why

the tongue is supplied by the hypoglossal nerve (12th cranial nerve) which originates from the medulla oblongata.

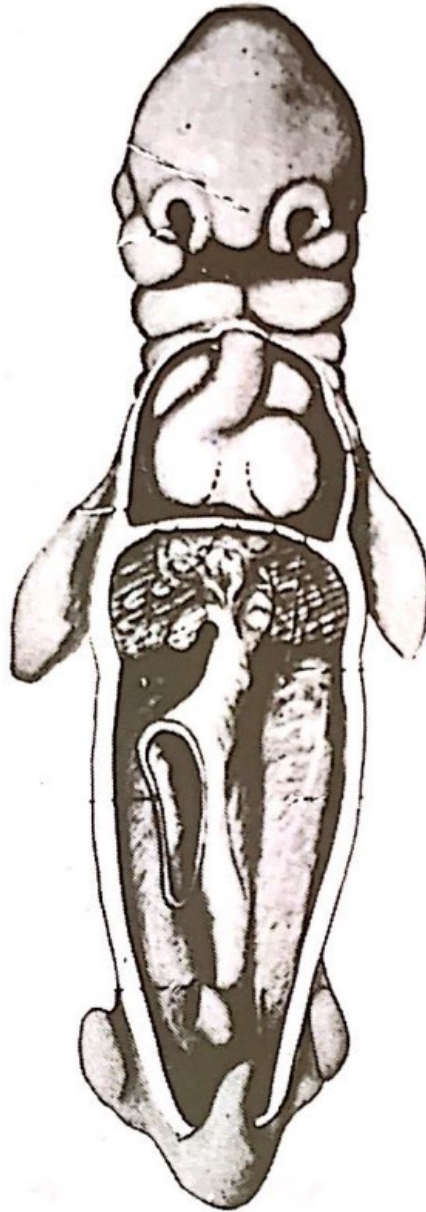


Fig. 57

An Embryo aged five weeks. The face is starting to take form, though it is quite ugly and bizarre. The frontal prominence, the nasal swellings and the maxillary and mandibular processes have already made their appearance. The upper and lower limb buds are like paddles and as yet structureless. The heart is forming. The diaphragm separates the heart from the liver. The gut is starting to make its simplest form.

All this will change. Both the external features and the internal organs will dramatically change after the sixth week, when the angel enters the womb as the Prophet says. The Quran verse (Sura 71/14) "He has created you in successive developmental stages."

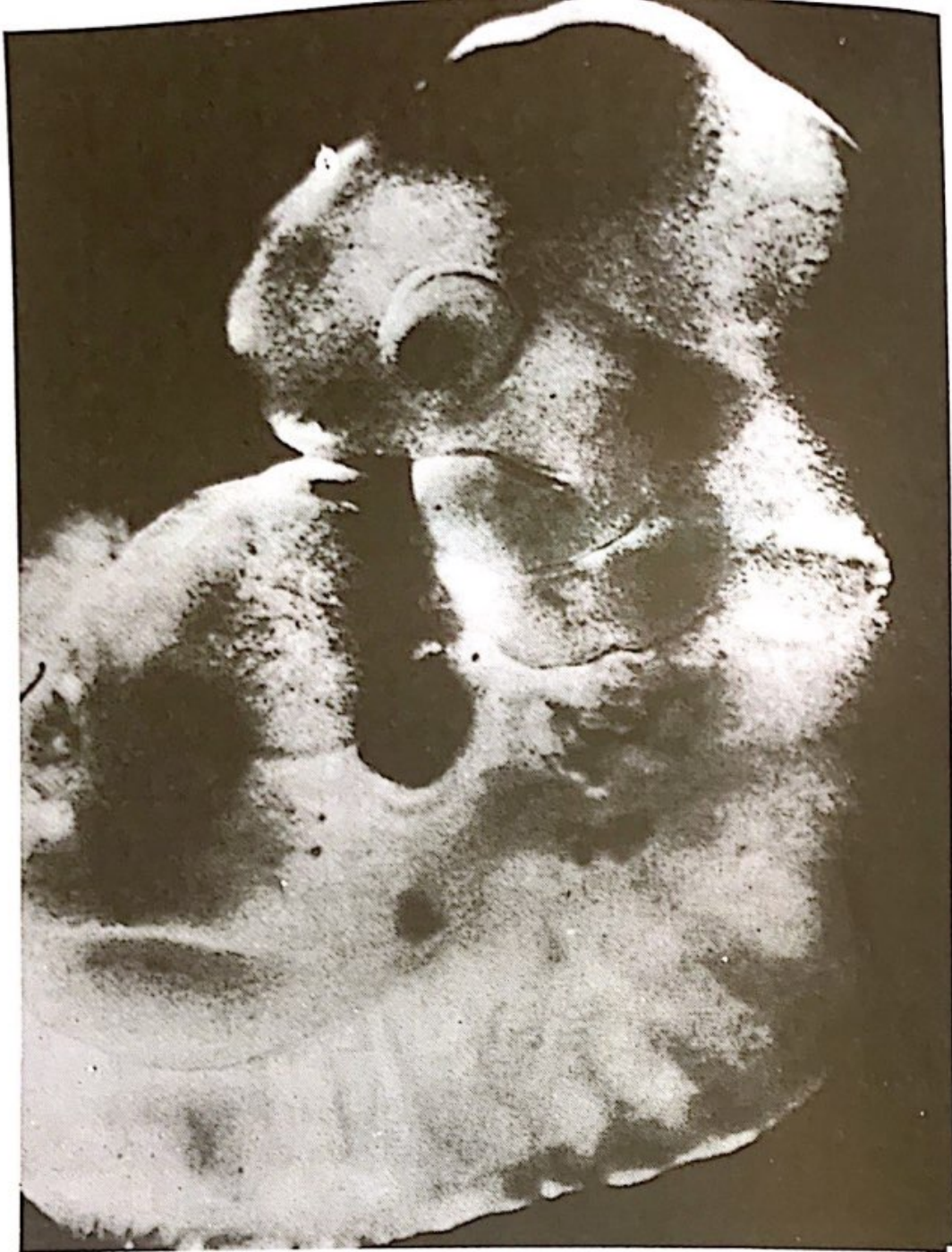

Fig. No. 58

An Embryo 30 days old. It is difficult at this stage to discern any human features. Although it resembles the embryo of a chick or a fish, the difference is innate and the embryo of a chick will never develop into a rabbit or a fish. It is determined long before it is formed, by the genes present in the ovum of the mother and the sperm of the father. "Out of a drop of fluid He created him, in which He determined his nature". Sura 80/19.

Genetic determination contradicts evolutionary Darwinism. The theory has to be circumvented to conform with the rapidly expanding science of genetics and molecular biology.

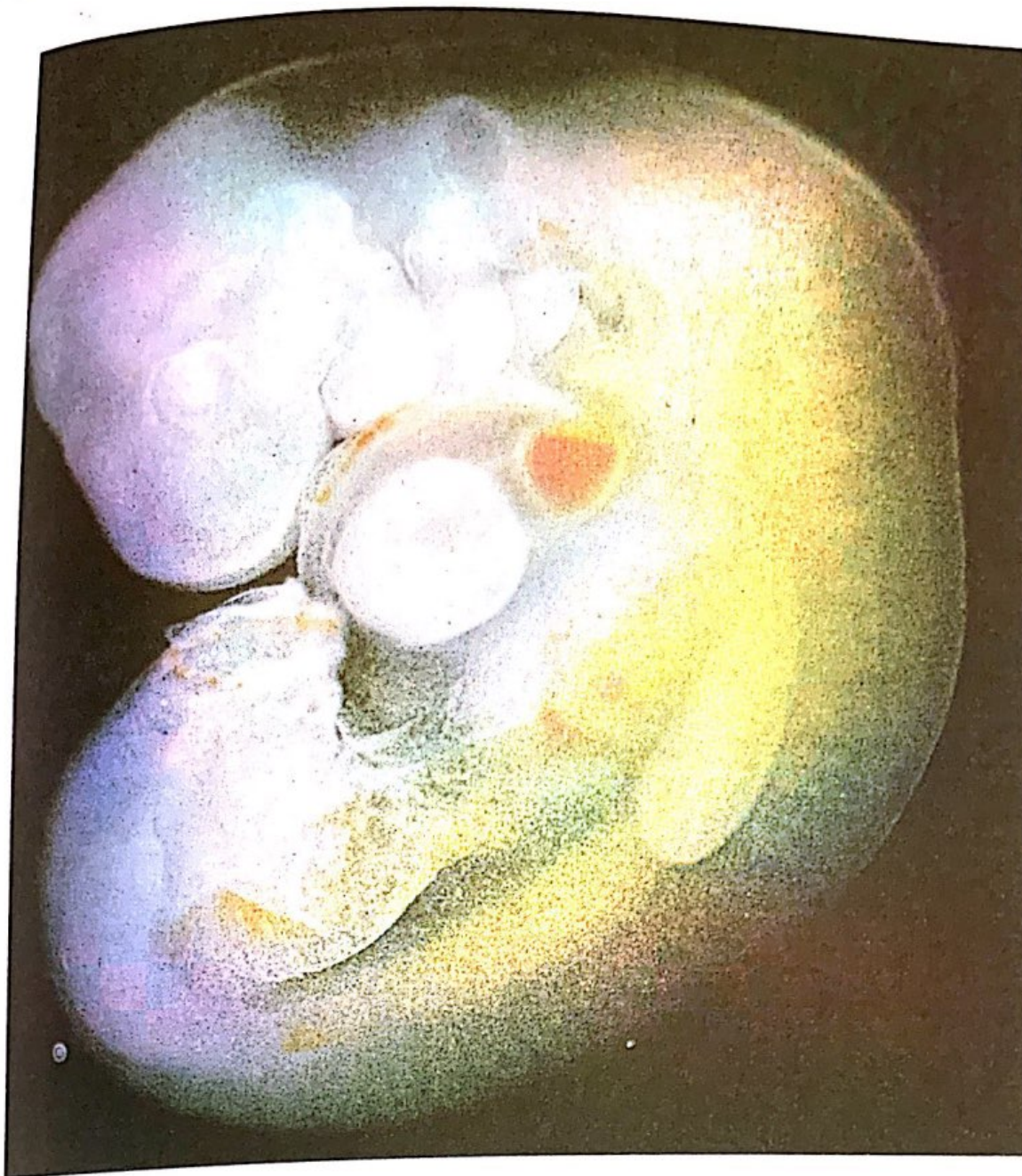


Fig. No. 59

Sura 71/13-14:

“What is amiss with you that you cannot look forward to God’s Majesty. He has created everyone of you in successive stages.”

The 7mm embryo (4th week) shows differentiation with a head made by the bulging of the neural tube forming the future brain. The optic cup is derived from the brain. The site of the chin and neck is still made up of pharyngeal arches which look like the gills of fish. The heart is literally under the chin. The upper and lower limbs are just budding.

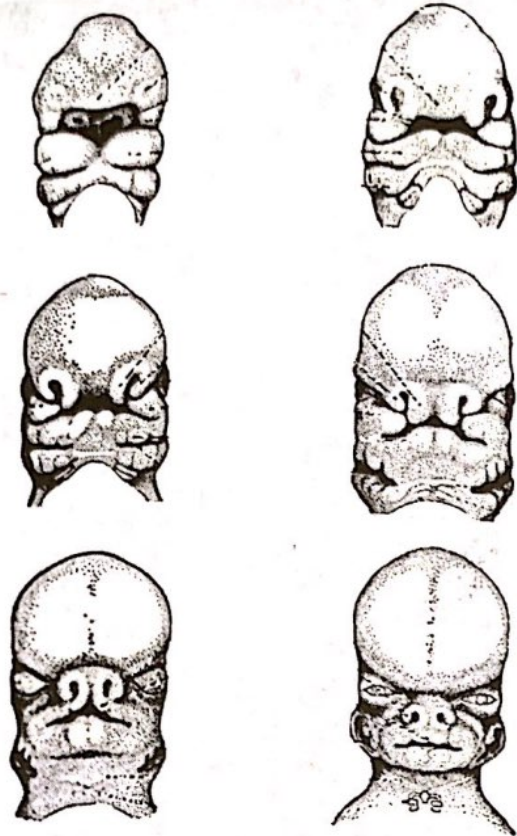


Fig. No. 60

Formation of the face

The face formation starts early. At the fourth week the Stomodeum (the primitive mouth opening) forms as a depression from the ectoderm. It is surrounded by the first pair of Pharyngeal arches.

During the fifth week five protuberant masses appear: The frontal prominence maxillary processes (pair) and mandibular processes (a pair).

A thickening of the ectoderm, called the nasal Placode, appears on each side of the frontal prominence. Two nasal swellings surround the nasal placode, which form the nose, the middle of the upper lip and part of the palate.

The cheeks form by union of maxillary process with the lateral nasal swelling, while the lower jaws, and the lower lip and the chin are formed by the mandibular processes.



Fig. No. 61
An Embryo 5 weeks old (6mm). This and the following pictures clearly depict the constant changing pattern of the shape of the forming embryo.
The Quran says:

قال تعالى :

« يخلقكم في بطون أمهاتكم خلقا من بعد خلق في ظلمات ثلاث » الزمر آية ٦

Sura 39/6:

“He creates you in your mother’s womb, one act of creation after another in three veils of darkness.”

وقال تعالى : « في أي صورة ما شاء ركبك » الانفطار ٨

Sura 82/8:

“In whatever form (and shape) He wills, He puts you together.”

وقال تعالى : « وصوركم فأحسن صوركم » التغابن ٣

Sura 64/3:

“And He gave you shape and made your shapes beautiful.”

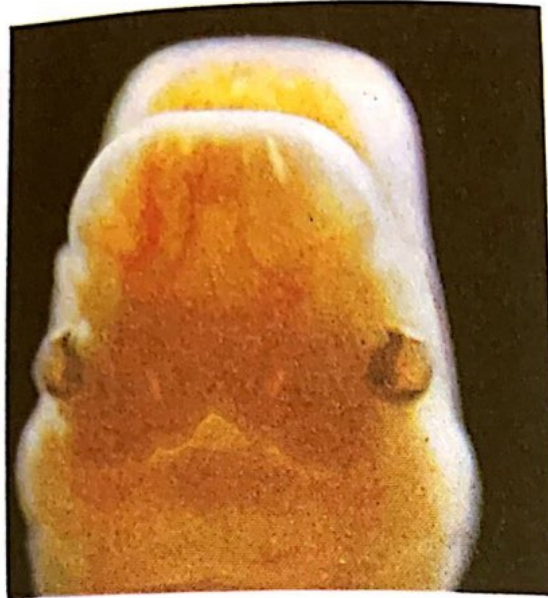


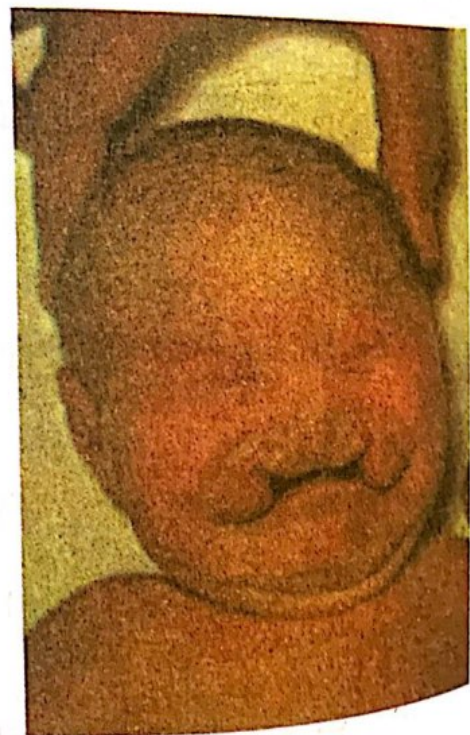
Fig. 62
The Embryo looks ugly at this stage. The five swellings are still separate from each other; viz. the frontal swelling, the two maxillary and the two mandibular swellings.

The nasal swellings both lateral and medial already made their appearance. The bulging eyes add to the ugliness of the face. But soon all this will be amended, and the embryo will acquire the human features beautifully designed. "And He gave you shape and made your shapes beautiful." Sura 64/3

Fig. 63
If the growth of the medial nasal swelling is incomplete, and if failure of the maxillary processes to merge with its corresponding nasal swelling occurs, the new born will have multiple defects varying from a simple hare lip to complete absence of the palate, and impairment of the growth of the nose.

It is the mercy of God, the creator, that we are born with no such defects.

The occasional and rare case shows His powers, and give an opportunity to consider His bountiful gifts.



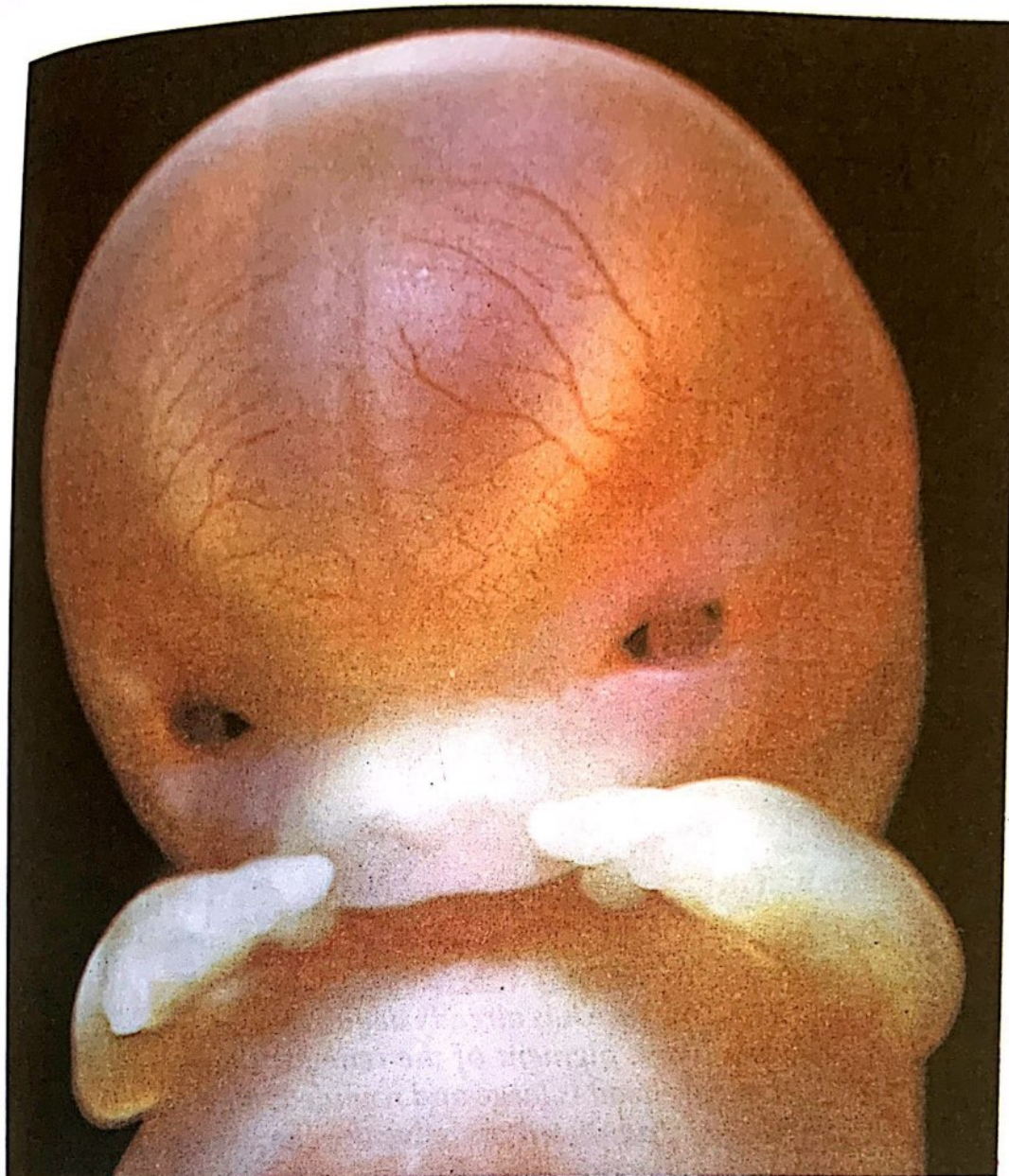


Fig. 64

At 5-6 weeks 1.5 cm embryo looks like a mouse rather than man. The plan however is laid down very early. Ibn AlQaim said in his book "Al Tibian Fi Aqşam Al Quran" seven centuries ago "Everyone who makes a shape in any material does not give it shape at once but gradually builds it up stage after stage. There are four stages:

- 1) the design is first made up in the mind of the Designer
- 2) concealed and obscure stage which cannot be detected by our senses.
- 3) a design or form which can be discerned, but vaguely
- 4) a complete clear form, which is followed by the soul entering it.

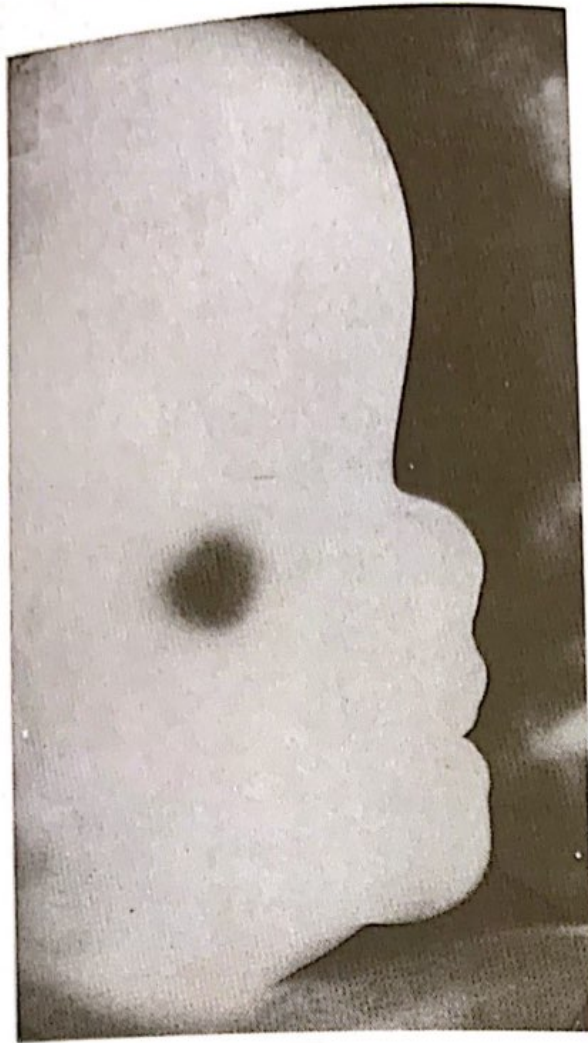


Fig. 65

At 11 weeks (5cm), the face has already acquired human features. The eyes are closed but the black pigment of the retina is shimmering through the delicate skin. The forehead is large and rounded; the nose is tiny and snub, the lips and chin are completed and give the characteristic human profile. The muscles under the skin are already contracting and the movements become gradually coordinated by the developing nervous system. Soon the sucking reflexes will be established and facial expressions will change the pattern of the mask face. This fetus weighs only 3/4 of an ounce (22 grams).

REFERENCES

- 1) Langman Medical Embryology
- 2) Langman Medical Embryology
- 3) Langman Medical Embryology

P391
P391
P391

Development of the Ears

(١) قال تعالى « وهو الذي أنشأ لكم السمع والابصار والأفئدة قليلا ما تشكرون »
المؤمنون ٧٨

Sura 23/78:

“It is He Who created for you the faculties of hearing, sight, feeling and understanding, (yet) how seldom are you grateful.”

(٢) « والله أخرجكم من بطون أمهاتكم لا تعلمون شيئا وجعل لكم السمع والابصار والأفئدة لعلكم تشكرون »
النحل ٧٨

Sura 16/78:

“And God has brought you forth from your mothers’ wombs knowing nothing — but He has endowed you with hearing, sight and minds so that you may be grateful to God.”

(٣) « انا خلقنا الانسان من نطفة أمشاج نبثليه فجعلناه سميعا بصيرا »
الانسان ٢

Sura 76/2:

“Verily it is We who have created man from a drop of mingled liquids, in order to try him; so We gave him (the gifts) of hearing and sight.”

In the above mentioned Quranic verses and wherever hearing and sight are mentioned as gifts from the benevolent God, the hearing is always mentioned first, denoting that hearing is even more important than seeing for the human being.

The language and the learning capabilities are dependent on the presence of normal hearing, more than anything else.

A child born deaf is unable to learn language and other things except with marked difficulty. A child born blind is handicapped, but it is much easier to teach him language and other capabilities.

The Holy Quran uses the singular form of the word "Al Sama" for hearing while using the plural for seeing "Al Absar."

The visual centres in the brain (occipital lobe) are duplicate while the hearing centre is considered as singular though represented in both temporal lobes of the brain.

In the embryo the ear develops from three distinct parts ⁽¹⁾: (1) *the external ear*: which serves as a sound collecting; develops from the dorsal portion of the first pharyngeal cleft and six surrounding mesenchymal swellings.

(2) *the middle ear*: Functions as a sound conductor from the exterior to the inner ear. It is made of the three ossicles, the malleus, the incus and the stapes, and the tympanic membrane (ear drum). The ossicles (small bones of the ear) arise from the mesoderm of the first and second pharyngeal arches. The tympanic membrane (ear drum) and cavity are derived from the entoderm of the first pharyngeal pouch and cleft.

(3) *the inner-ear* is made up of two parts:
a) *auditory* which converts the sound waves into nerve impulses, which are conducted by the auditory nerve to the brain.
b) *Vestibular part* which registers the changes in equilibrium and conducts them to the brain via the vestibular nerve.

Any change in posture is registered by the utricle, saccule and semicircular canals, which comprise the vestibular apparatus. It is conveyed to the brain by the vestibular nerve.

The first indication of the developing ear is found at approximately 22 days. It appears as a thickening of the surface ectoderm on each side of the hind brain (rhombencephalon.) This thickening is called the otic placode. It invaginates and transforms into auditory (otic) vesicle (bubble). This bubble develops into two components; one concerned with hearing (cochlea); the other is concerned with equilibrium (saccule, utricle and semicircular canals.) These make their first appearance in the sixth week. By the eighth week they are already approaching the final preborn status.

The ears of the fetus function as early as the fourth month. ⁽²⁾ The fetus can hear his mother's voice, the rumblings of her stomach and the sounds she makes while eating and drinking. It can also hear external sounds in the environment, be it a crying brother, a shouting father or an orchestra played and shown in the house T.V. set.

A new born is already used to an environment which is not silent.

The Sunna "the acts and deeds of the Prophet (peace be upon him)"

is to make "Azan" "Call for prayers" in the right ear, and iqama "Call for starting the prayers" in the left ear, the moment the child is born.

This is to acquaint the newly born with the message of Islam from the earliest moment.

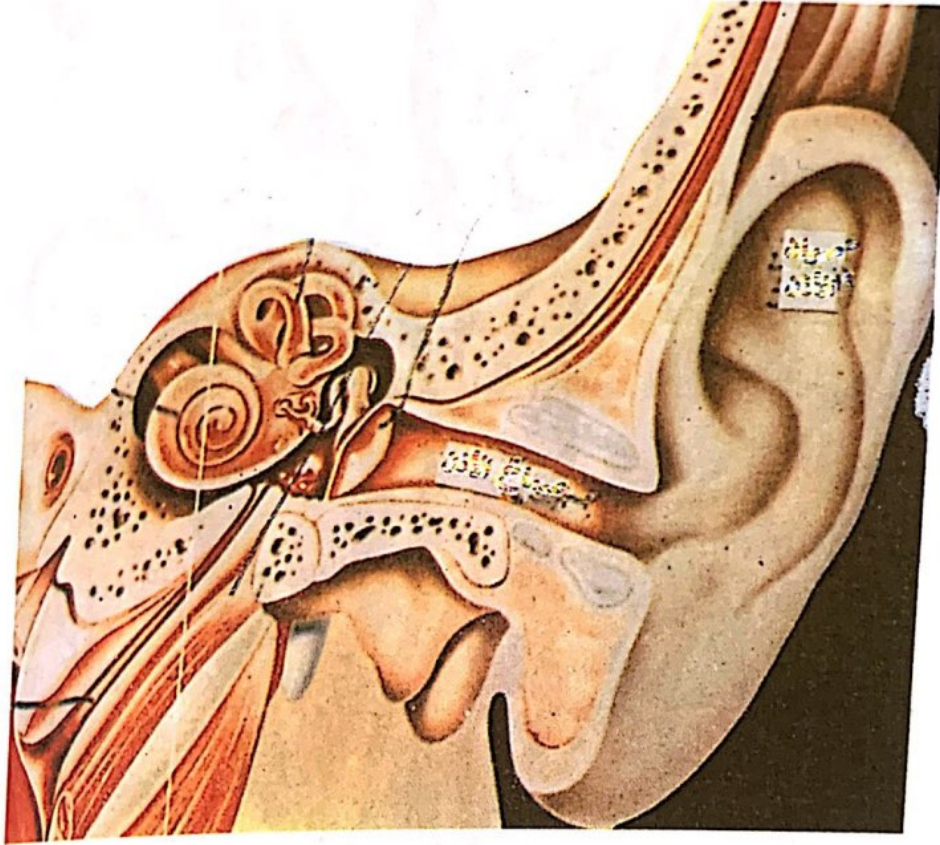


Fig. 66

The internal ear is made up of hearing apparatus (Cochlea) and Vestibular apparatus for equilibrium (Utricle, Saccule, and semi-circular canals.)

Middle ear is made up of 3 small bones and eardrum

The external ear is made up of the Pinna and the external auditory meatus.

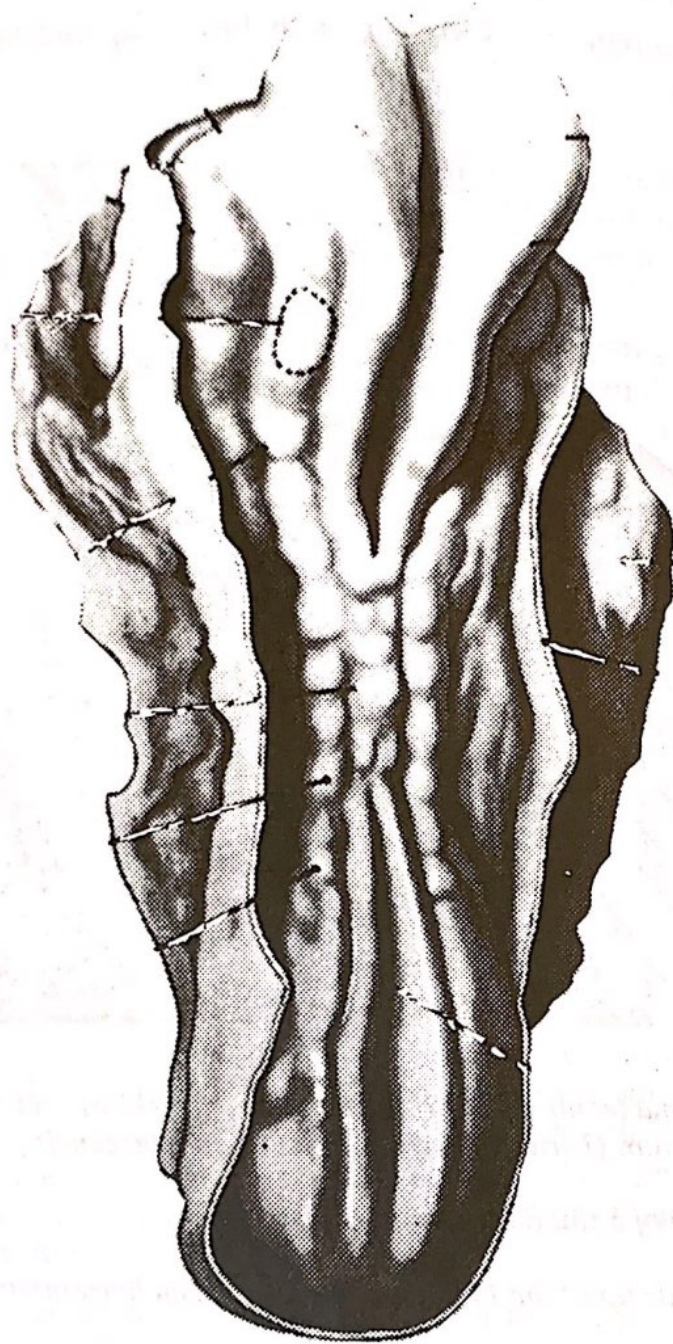

Fig. 67
The first appearance of the otic placode (thickening of the surface ectoderm) on each side of the hind brain, occur in a 22 days embryo, whereby the somites are still forming. During the fifth week it becomes a vesicle, and by the end of the sixth week (at the time of entry of the angel) it is transformed into hearing and equilibrium apparatus. By the eighth week the work is almost finished.

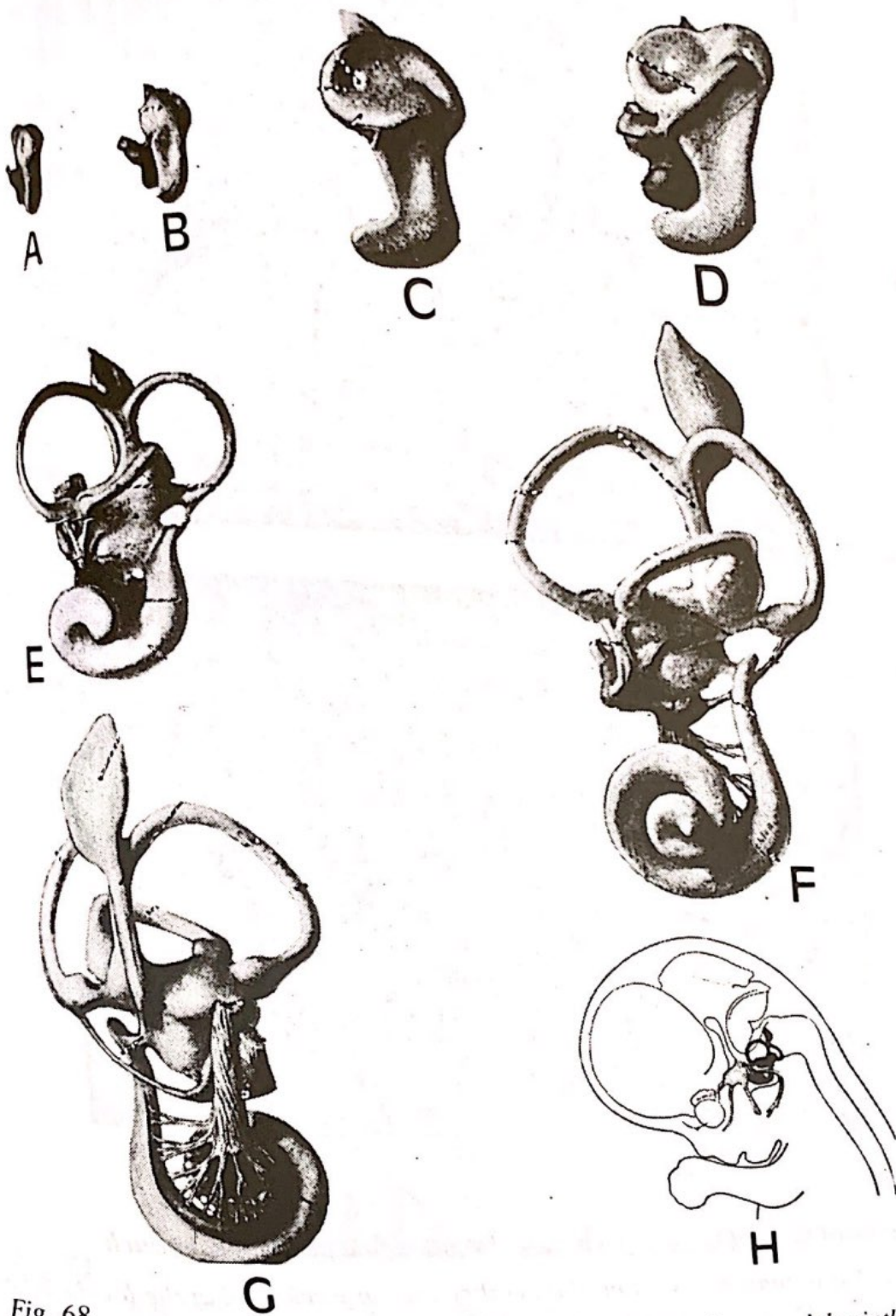


Fig. 68
 Development of the internal ear and the formation of membranous labyrinth. (Figs A and B) show the otic vesicle elongating at the 5th week, whereby a cochlear portion and vestibular portion appear. At the sixth week (C and D) the beginning of the semicircular canals appear. By the seventh week (E and F) the different parts of the internal ear are formed; and by the eighth (G) there is little to add until birth.

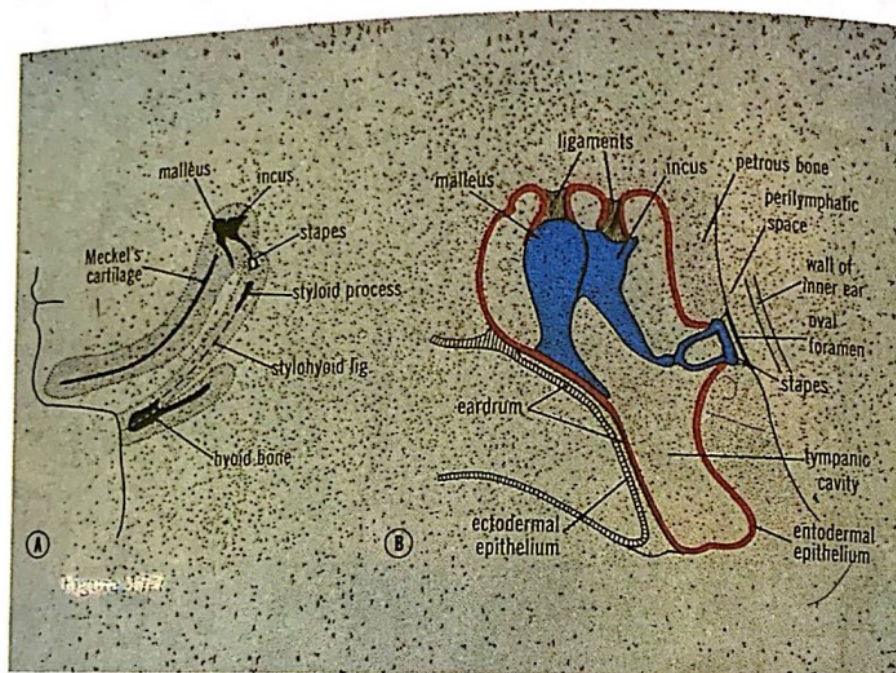
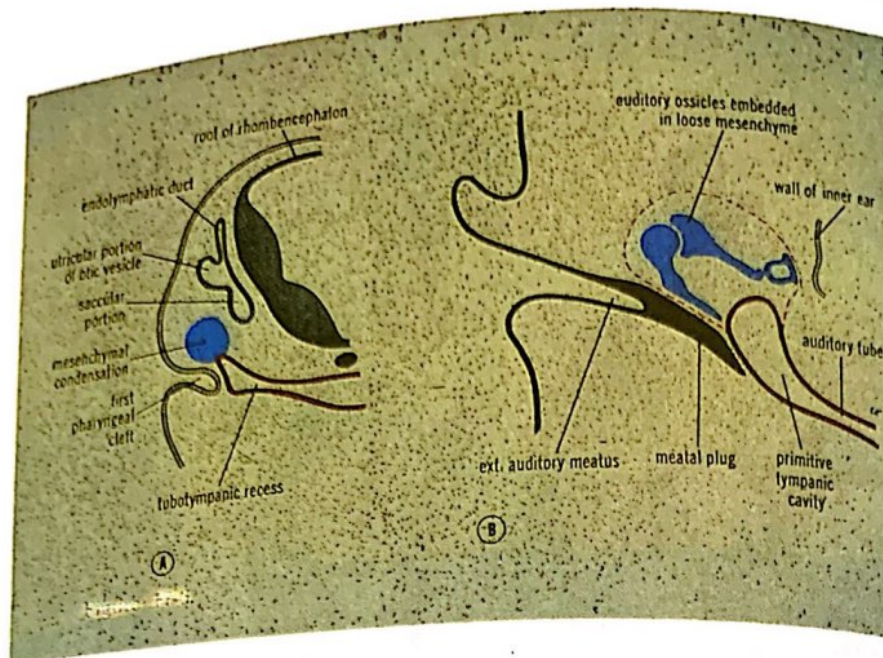


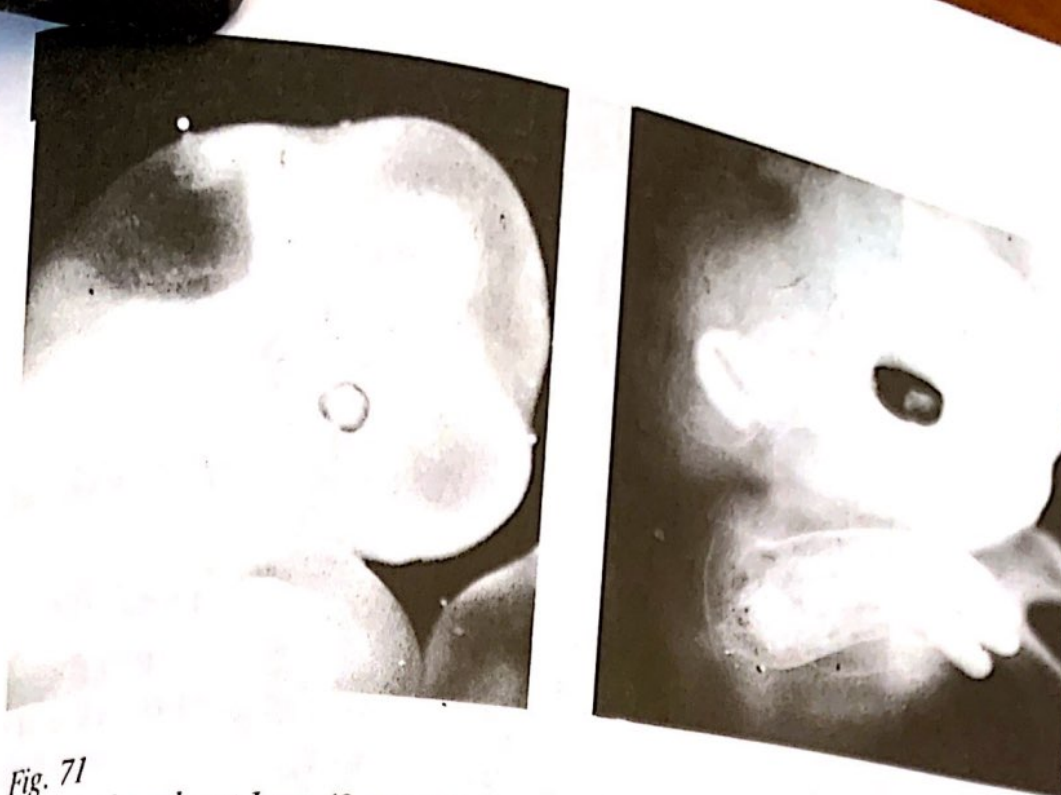Fig. 69

Fig. 70

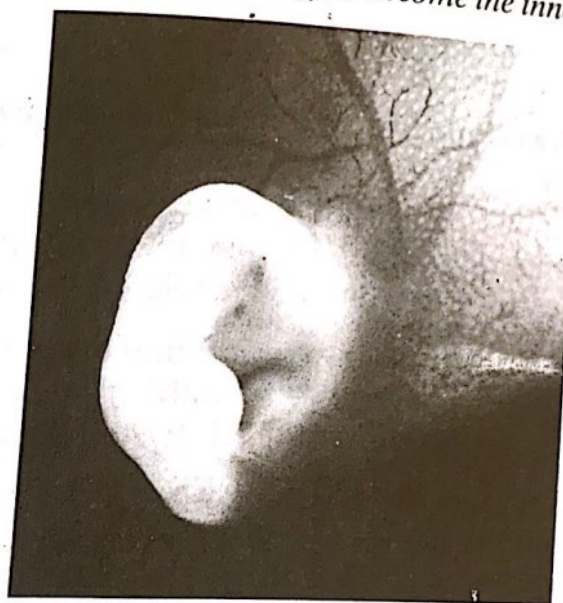Formation of the middle ear which starts from the first pharyngeal pouch.

Fig A is a transverse section of an embryo seven weeks old at the level of the hind brain. The mesoderm condenses to form the ossicle of the middle ear (B). A meatal plug forms and separates the external ear from the middle ear. This plug is later on slit to form the external auditory meatus.

The Prophet (peace be upon him) says in his prayers: "Glory be to God Who split open my hearing and sight."



*Fig. 71
At 5 weeks, about 1 cm (0.4 inch). The developing outer ear looks like a somewhat wrinkled mouth just above the shoulder. Farther up you can catch a glimpse of a pale, oval contour between the outer ear and the depression of the rear brain curve — that is the bubble that was pinched off to become the inner ear.*



*Fig. 73
In the two pictures above and the large picture to the right, we see the outer ear taking shape, from simple skin folds at eight weeks, the “cauliflower ear” at four months, and the practically complete ear just over a month later. The shell-like part of the ear is known as the concha. The edge will start to roll in, and the small nick on top that most of us have means that the rolling was not quite perfect.
From “A Child is Born” by Lennart Nilsson.*

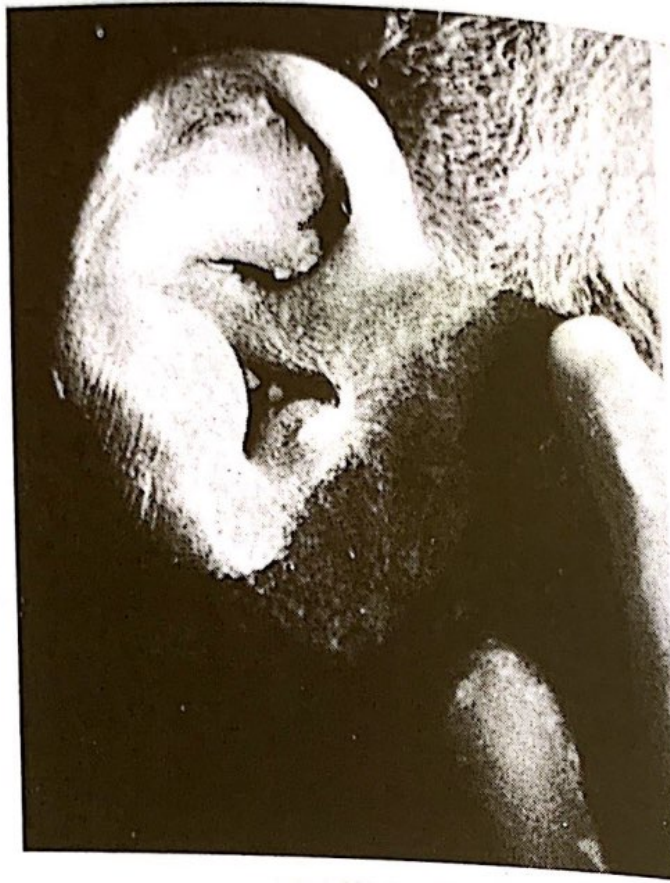

Fig. 74
The external ear of a five months fetus. It is similar to that of a new born and even to that of an adult.

REFERENCES

Langman: Medical Embryology, 3rd Edition
Lennart Nilsson: A child is born

P 378
P 116

Development of the Eyes

قال تعالى : « وهو الذي أنشأ لكم السمع والابصار والأفئدة قليلا ما تشكرون »
المؤمنون ٧٨

Sura 23/78:

“It is He WHO created for you the faculties of hearing, seeing, feeling and understanding, (yet) how seldom are you grateful.”

« والله أخرجكم من بطون أمهاتكم لا تعلمون شيئا . وجعل لكم السمع والابصار والأفئدة لعلكم تشكرون »
النحل ٧٨

Sura 16/78:

“And God has brought you forth from your mothers' wombs knowing nothing — but He has endowed you with hearing, sight and minds so that you may be grateful.”

Many Quranic ayas (verses) mention the faculties of hearing and sight as gifts from the benevolent God. It also stresses that we acquire our knowledge via these channels to the minds.

It contradicts Plato's philosophy which claims that we are born with already innate knowledge. Man only recollects these things, as his soul has known them long before it dwelt in his body.

The above Quranic Ayas emphatically stress that man is brought forth from his mother's womb knowing nothing. He acquires knowledge through his senses mainly visual and auditory. The mind grasps, arranges and comprehends these sensations.

The creation of an eye is a remarkable example of the interaction between the developing brain and the thin skin of the embryo.⁽¹⁾

First the anterior part of the brain sends out a hollow stem on each side, on the 22nd day. This stem is called the optic stalk. The end of the stem bulges forming a vesicle, which when approaching the surface,

become invaginated forming the optic cup. The cup is made up of two layers, separated by a lumen, called the intra retinal space. With further development the lumen disappears, and the two layers are then opposed to each other. ⁽²⁾

Along the invagination which extends from the cup to the stalk runs the hyaloid artery. The groove is known as the choroid fissure.

During the seventh week lips of the choroid fissure fuse, and the mouth of the optic cup then becomes a round opening. ⁽³⁾

Instructions (by the angel who enters the womb at 40th-42nd day, according to Hadith of the Prophet) are forwarded to the surface ectoderm (the skin), "Make a lens!". The skin then pinches off a bubble, which is placed in the opening of the cup, forming a lens. ⁽⁴⁾

By the end of the seventh week, the nucleus of the lens is formed. ⁽⁵⁾ This conforms with the Hadith of the Prophet narrated by Muslim that angel enters the womb at 40th-42nd day and starts forming the different organs including the eye.

New fibres are added to the nucleus of the lens, the lens being lamellar. Later on it loses its blood supply and become transparent.

Similarly the surface ectoderm (future skin) forms the cornea, a thin transparent curved part of the skin which covers the pupil in front of the lens.

On the front of the lens the iris grows from the edges inwards. The muscles of the iris which control the eye aperture, the pupil, are the only muscles of the body derived from ectoderm. All the other muscles of the body are derived from mesoderm.

At the end of the fifth week, the eye primordium is completely surrounded by loose mesenchyme. After the sixth week (i.e. after the angel has entered the womb) this mesenchyme differentiate into: i) a loose inner tissue which become highly vascularised and pigmented, the choroid ii) a thick outer layer which forms the Sclera.

The choroid is continuous with the piamater of the brain and the sclera is continuous with the duramater (the thick covering of the brain).

The outer layer of the optic cup develops into the pigment layer of the retina, while the inner 4/5 of the optic cup transforms into the rods and cones (the sensitive parts to light), the inner and outer nuclear layers and the ganglion cell layer. The ganglions are nerve cells, their fibres form the optic nerve which is connected to the brain.

These changes start at the seventh week of intra-uterine life, which

agrees with the above mentioned Hadith of the Prophet, whereby an angel sets to work amazingly at the end of the sixth week and the beginning of the seventh week.

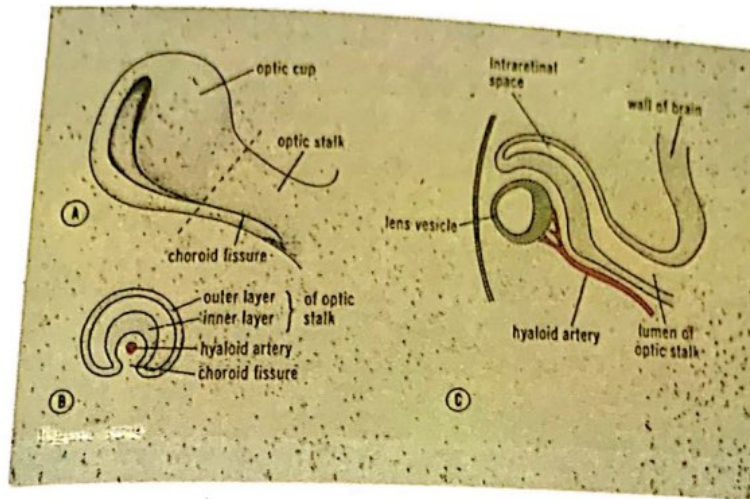


Fig. 75.

Fig A) The optic cup and optic stalk of a six week embryo.

B) Transverse section through the optic stalk indicates as in A showing the hyaloid artery in the choroid fissure.

C) Section through lens vesicle, the optic cup and optic stalk

(From Langman: Medical Embryology)

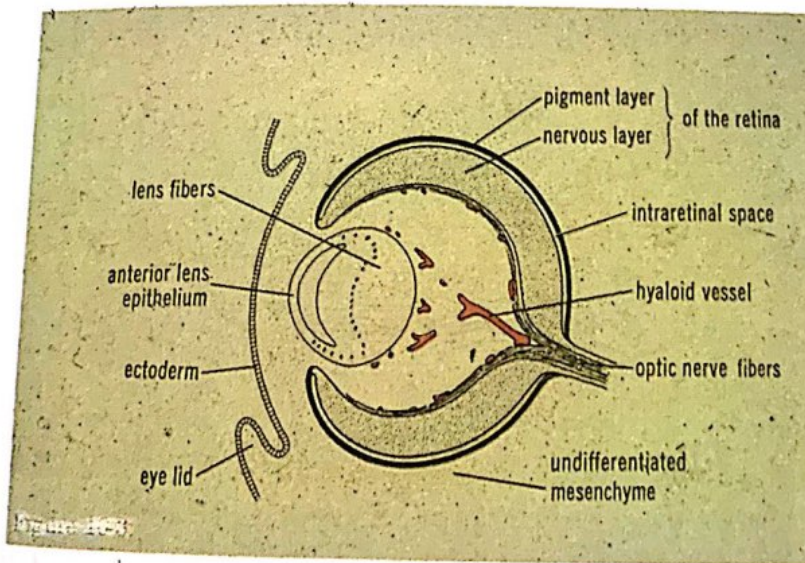


Fig. 76

Antero posterior section through the eye of a seven week embryo. The eye is embedded in mesenchyme. The fibres of the optic retina converge toward the optic nerve.

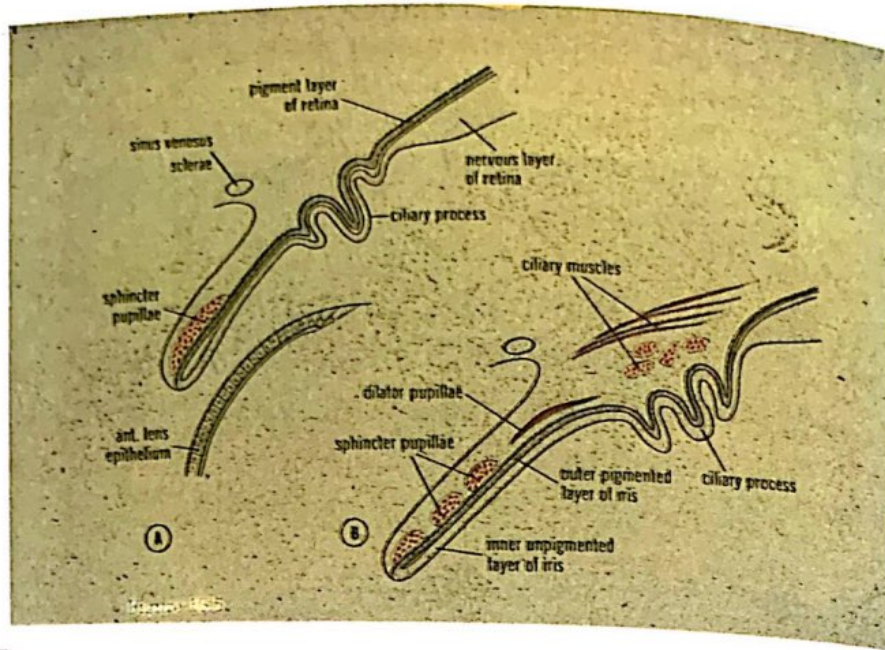
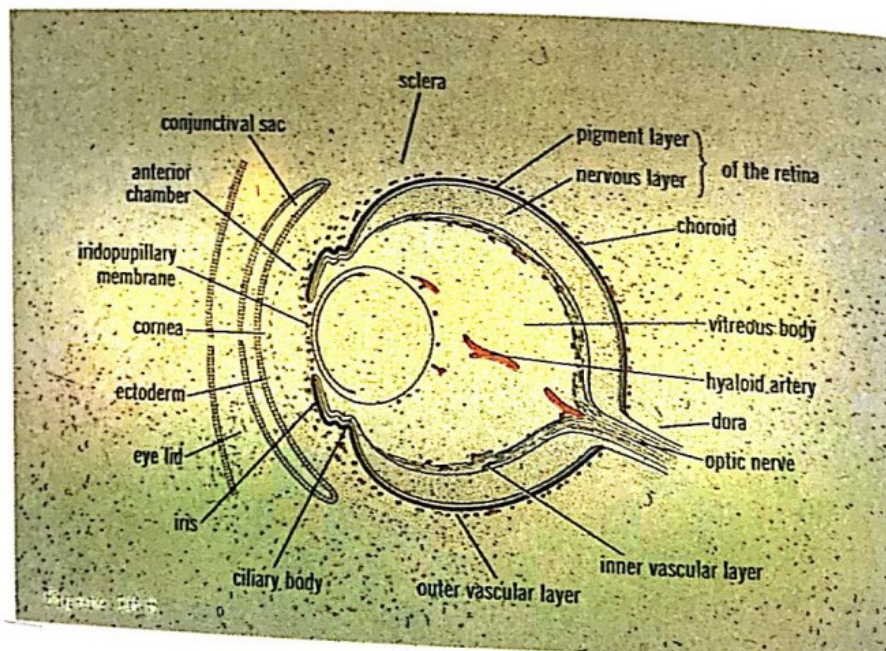


Fig. 77
 Development of the Iris and ciliary body. The sphincter and dilator pupillae (the muscles which control the pupil) develop from ectoderm unlike the muscles of the whole body which develop from mesoderm.



15 week Embryo the eye is almost completely developed. The conjunctival sac is formed in front of the cornea. The lens is still laminar and the hyaloid artery is degenerating inside the vitreous body. The choroid, sclera and retina are well established. Even the anterior chamber is recognisable at this stage.

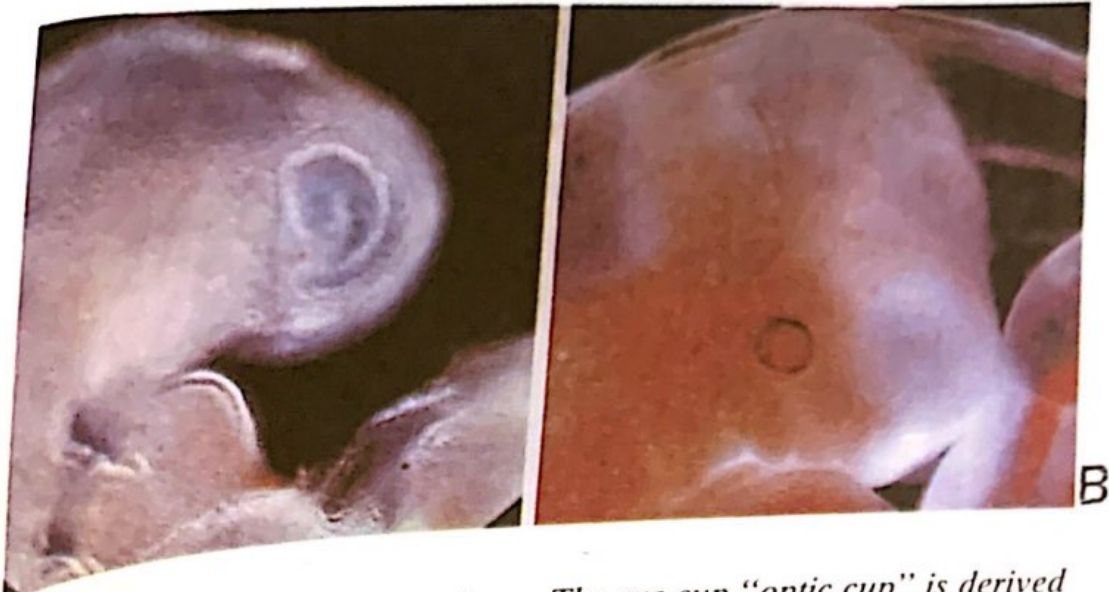

Fig. 79
 Fig A. At four weeks, 4mm embryo. The eye cup "optic cup" is derived from the ectoderm. The faint oval in the middle is thin bubble pinched off by the skin to form a lens.
 Fig B. At 5 weeks, (7-8 mm) dark pigment has already formed in the wall of the cup, forming the future retina.

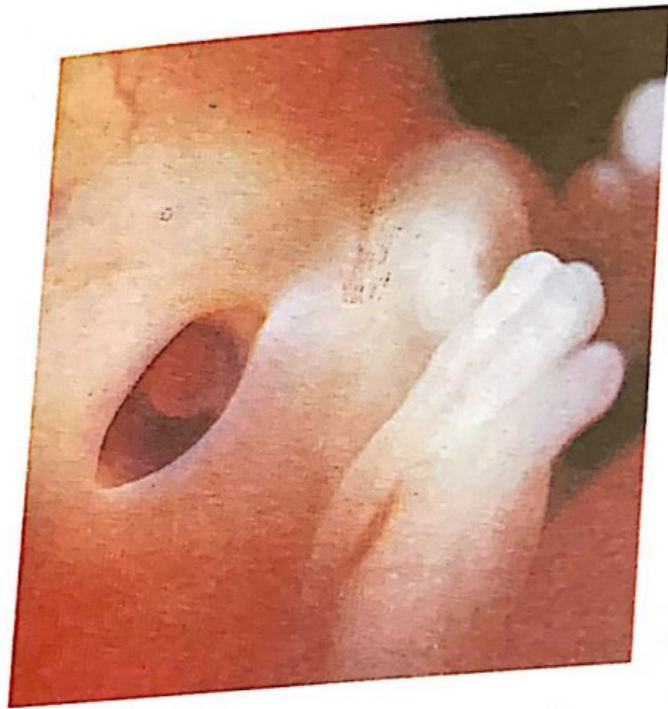

Fig. 80
 At 8 weeks (3 cm), the early eyelids are forming. The pigment of retina is shimmering through the developing lens and cornea.

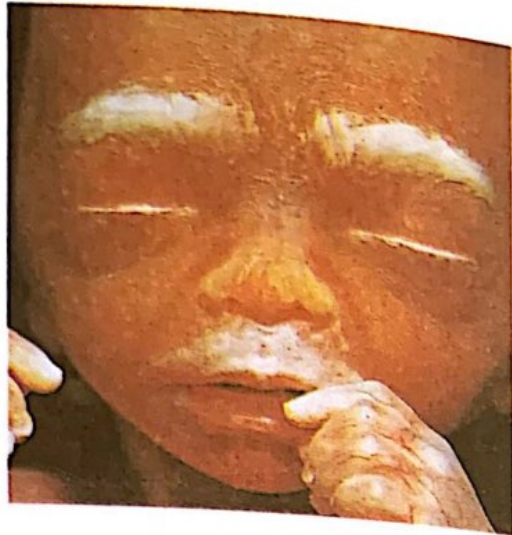


Fig. 81

At 20 weeks (21 cm), the eyelids are formed and the eyes are closed. The eyelids appear at the third month and open again during the seventh month.

The Prophet (peace be upon him) says "Glory be to God WHO split open my hearing and sight."

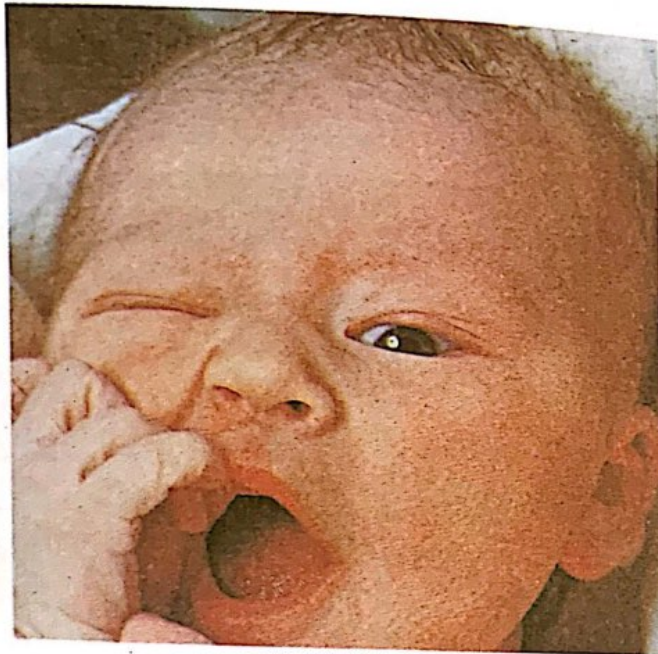


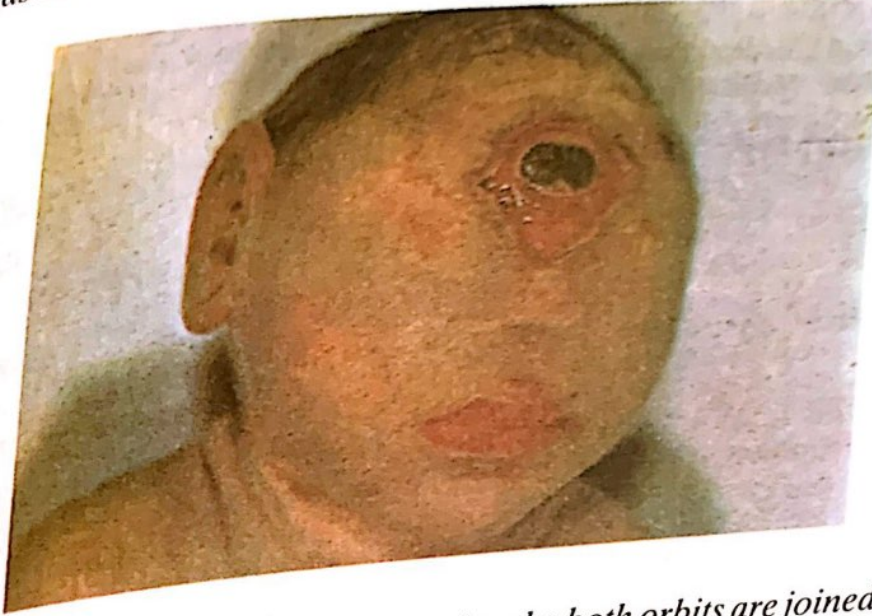Fig. 82

A new born baby starts looking around. His eye registers the pictures like a camera and sends them to the brain to process them like a film is processed in photographers laboratory.

To discern and comprehend these pictures, is an elaborate complicated process of the brain, which takes time to grasp and learn. So, a newly born baby can see but cannot comprehend the pictures he sees.

Our eyes are not only the windows of our hearts, but are the windows through which our brains acquire knowledge.

Sura 16/78 says: "God has brought you forth from your mothers' wombs knowing nothing, but He has endowed you with hearing, sight and minds so that you may be grateful."



*Fig. 83
The cyclops: A congenital abnormality whereby both orbits are joined, and there is only one median eye. Here two eye balls are connected in one orbit. The nose is not developed. Both cerebral hemispheres of the brain are united and underdeveloped. In this cyclops one cerebral hemisphere, one optic nerve and no olfactory nerves were found at autopsy.*

The child died three days after delivery.

This is a rare type of congenital abnormality so that we may consider how God can shape man in any form He wishes.

« في أي صورة ما شاء ركبك » الانفطار ٨

Sura 82/8:

"In Whatever form He wills, does He put thee together."

There are other congenital abnormalities. Fortunately they are very rare.

« لقد خلقنا الانسان في أحسن تقويم » التين ٤

"Verily, We create Man in the best conformation." Sura 95/4.

REFERENCES (Eye)

- 1) Lennart Nilsson: "A child is Born" P 92
- 2) Langman "Medical Embryology" P 368
- 3) Langman "Medical Embryology" P 370
- 4) Lennart Nilsson "A child is Born" P 92
- 5) Langman P 372

Three Veils of Darkness

قال تعالى : « يخلقكم في بطون أمهاتكم خلقا من بعد خلق في ظلمات ثلاث »
الزمر ٦

Sura 39/6:

“God creates you in the womb of your mothers, one act of creation after another, in three veils of darkness.”

The three veils of darkness were explained by the commentators of Holy Quran ⁽¹⁾ to be: the abdominal wall, the wall of the womb (uterine wall) and the sacs surrounding the fetus.

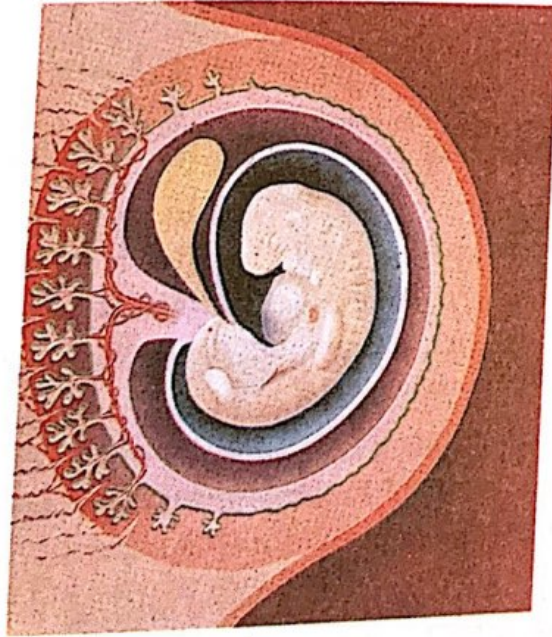


Fig. 84

The uterine wall forms the second veil of darkness; the first being the abdominal wall. The third is the membranes in which the embryo is enclosed; these are three, the amnion which is a thin sac filled with fluid surrounding the embryo from all sides and protecting it, followed by the chorion and finally by the decidua which is the most inner part of the uterus (womb) which does not participate in formation of the placenta.

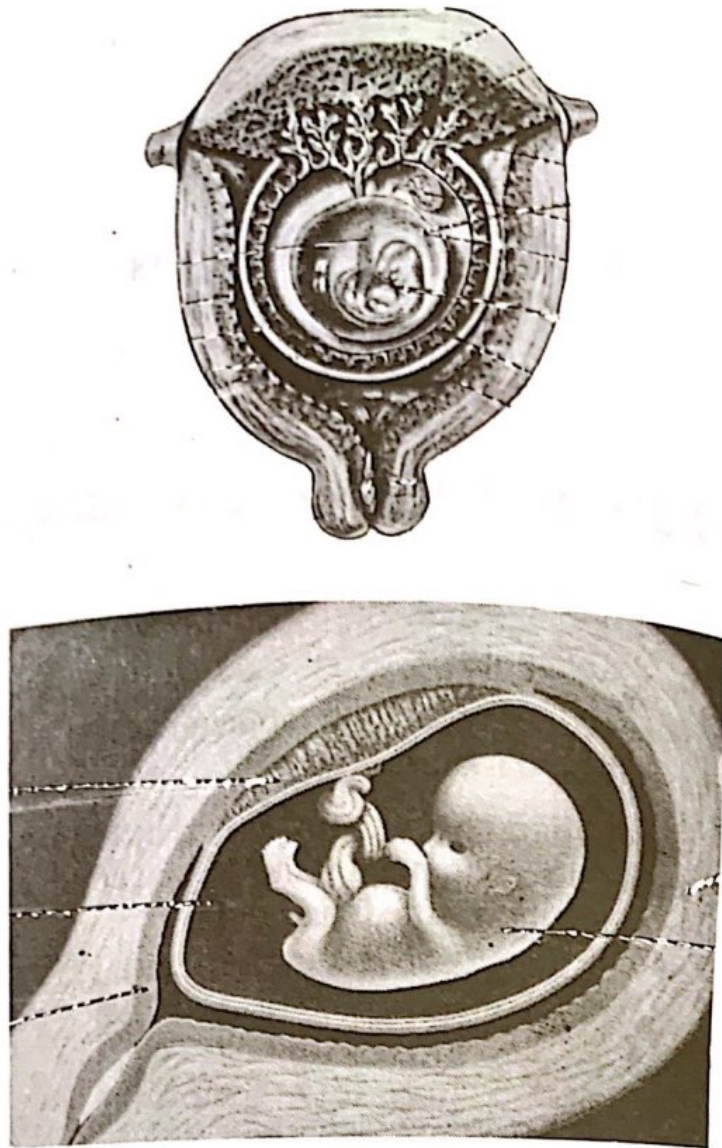


Fig. 86

The two pictures illustrate well, the second layer, the uterine wall, and the third layer which is made up of three sacs, the amnion, the chorion and the decidua. The first layer is made by the anterior abdominal wall.

Each of these three layers is also made up of three consecutive layers. The abdominal wall is made up of three muscle layers: external oblique sheet of muscle, followed by the internal oblique muscle, and then transversus muscle.

Similarly, the wall of the uterus (womb) is made up of three layers: the epimetrium (which covers the womb), the myometrium (the muscle layer of the womb) and the endometrium (the inner layer of the womb.)

The myometrium is also made up of three layers of muscles, longitudinal, followed by interwoven figure of 8 layer, which is followed by a circular layer.

The sac layers which surround the embryo (later on fetus), are also made up of three membranes: the amnion, the chorion and the decidua.

The amnion is a membranous sac that surrounds the embryo (later on the fetus).

Early in the development of fertilized ovum, when it forms a ball like structure, the blastula, a slit like cavity appears between the embryonic disc (the embryo proper) and the trophoblastic covering which invades the uterine wall. By the seventh day a roof appears which is made of thin sheet of cells probably derived from the cytotrophoblasts. The floor of the cavity is made up from the ectoderm (outer layer) of the embryonic disc.

As the amnion enlarges it gradually obliterates the chorionic cavity (which forms the second sac), and sheaths the umbilical cord.

The sac become filled with a watery fluid (98% water) which is derived from the maternal blood by transport across the amnion. The fetus later on excretes urine, and as much as 500 ml are added daily. The urine of the fetus is mainly made of water, as the placenta still functions as the kidney of the fetus and excretes all the waste products.

The amniotic fluid increases slowly from 30 ml at 10 weeks to 350 ml at 20 weeks, and 1000 ml by 37 weeks. The volume then decreases sharply.⁽¹⁾

If the volume of the amniotic fluid is decreased, the case is known as oligohydramnios. It results from either placental insufficiency or renal agenesis (absence of kidneys.)

However, if the amniotic fluid is increased to two litres the case is known as Poly hydramnios.⁽²⁾ It results from

- i] multiple pregnancies e.g. twins
- ii] congenital malformation of the central nervous system e.g. anencephaly, or oesophageal atresia.

The amniotic fluid is not static it is changed completely every three hours.⁽³⁾ From the beginning of the fifth month the fetus swallows its own amniotic fluid and it drinks about 400 cc daily. If there is oesophageal atresia (gullet blocked) or through lack of nervous control of swallowing as in anencephaly, the fetus cannot swallow the amniotic fluid which accumulates causing Poly-hydramnios.

Normally the swallowed amniotic fluid is absorbed through the gut and hence passes again to the circulation first of the fetus and then of the mother.

The amniotic fluid has many functions:

- 1) It protects the fetus from injuries and jolts by forming a protection cushion.
- 2) It prevents adherence of the amnion to the embryo. This is believed to

- protect against many congenital abnormalities.
- 3) It permits symmetrical external growth of the embryo.
 - 4) It controls the body temperature of the fetus.
 - 5) It enables the fetus to move freely, thus aiding the development of muscles and bones.
 - 6) It can be withdrawn and examined by the process called *amniocentesis*.
- The amniotic fluid can be withdrawn at 15-16 weeks of gestation. A syringe is inserted through the lower abdominal wall, and through the uterine wall towards the amniotic sac, and the fluid is aspirated under the guidance of ultrasound.

The indications of amniocentesis are:⁽⁶⁾

- 1) Late maternal age (40 years). With increased maternal age Chromosomal and Congenital abnormalities increase markedly.
- 2) Previous birth of a child with trisomy e.g. Down's Syndrome.
- 3) The mother carrying an X linked recessive disorder e.g. hemophilia.
- 4) Neural tube defects in the family.
- 5) Carriers of inborn error of metabolism.
- 6) Chromosomal abnormality in either parent.

The amniotic fluid is examined for:

- 1) Fetoproteins, (chemical substances) which increase markedly in cases of open neural tube defects.
- 2) Sex chromatin pattern to determine the sex of the fetus in cases where sex linked disorders are suspected.
- 3) Cell cultures: to determine inborn errors of metabolism and chromosomal abnormalities like Down's Syndrome.

Ultra Sonography is advancing nowadays and they are replacing other invasive or ionizing methods. Prenatal diagnosis of many fetal abnormalities e.g. anencephaly, hydrocephaly, ascites and renal agenesis can be easily diagnosed by ultrasound. The sex of the fetus can also be determined in the majority of cases.

The second membrane or sac in the Chorion

The chorion forms early after the implantation of the ball like blastula into the endometrium (the inside of the womb). The invading cells, called Syncytiotrophoblasts, form finger like processes, which are solid at first. By the beginning of the third week the trophoblast is characterised by a great number of primary solid villi ⁽⁷⁾. Soon loose connective tissue appear inside these primary villi and convert them to secondary villi (16th day onwards). By the twentieth day blood vessels invade these secondary villi, transforming them to tertiary villi ⁽⁸⁾.

By the 21st day blood starts to circulate through the capillaries of chorionic villi. The villi absorb nutriment from the maternal blood, and excrete the waste material from the embryo and delivers it to the maternal circulation.

Villi arborise like a tree and soon cover the whole embryo including its amniotic sac.

The villi that are attached to the maternal side are called Stem or anchoring villi, while those away from the maternal side are called branch villi.

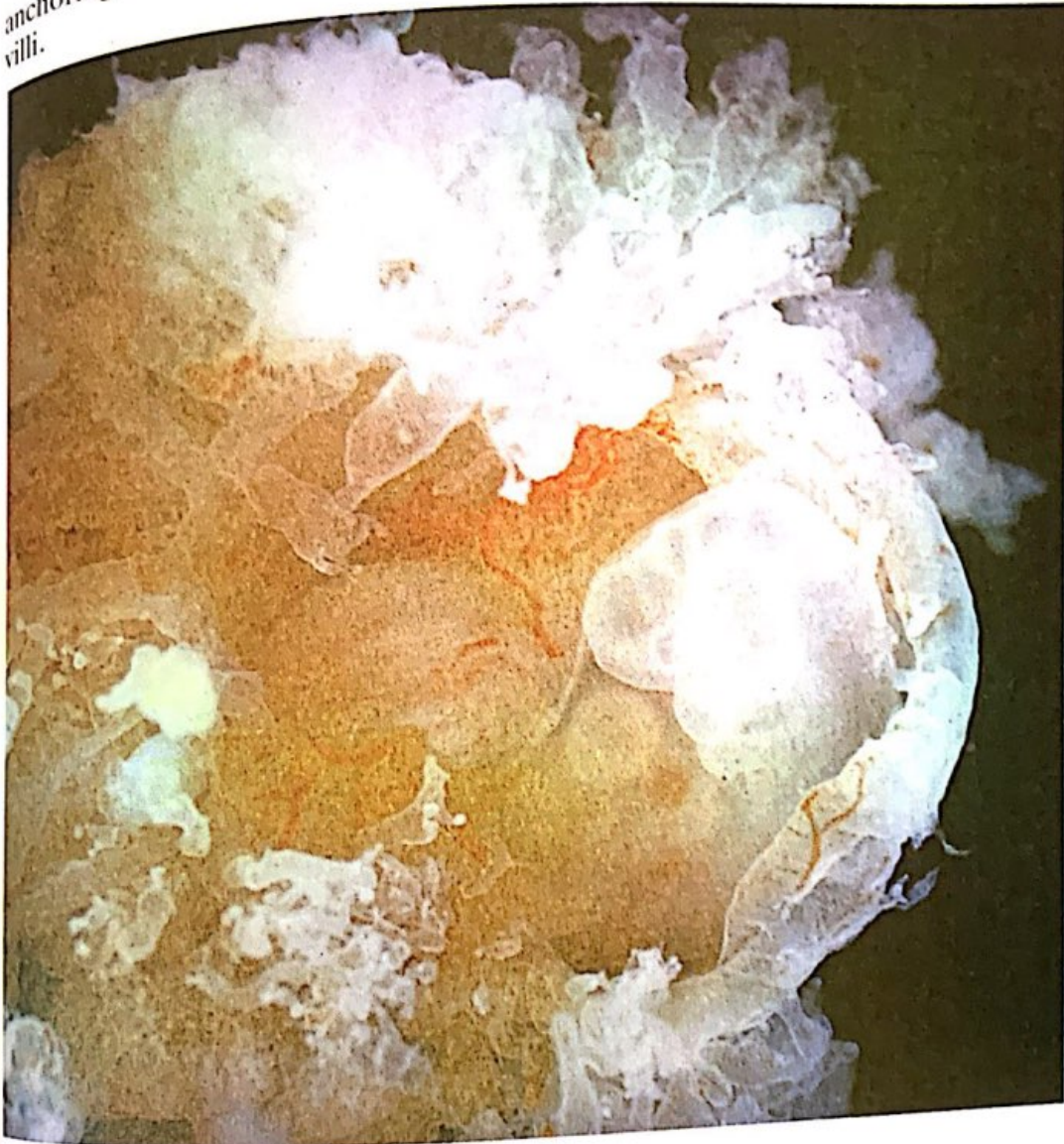


Fig. 87
The arborising chorionic villi are seen covering the amniotic sac, which is slit open to show a 7 mm (4 1/2 weeks) embryo.

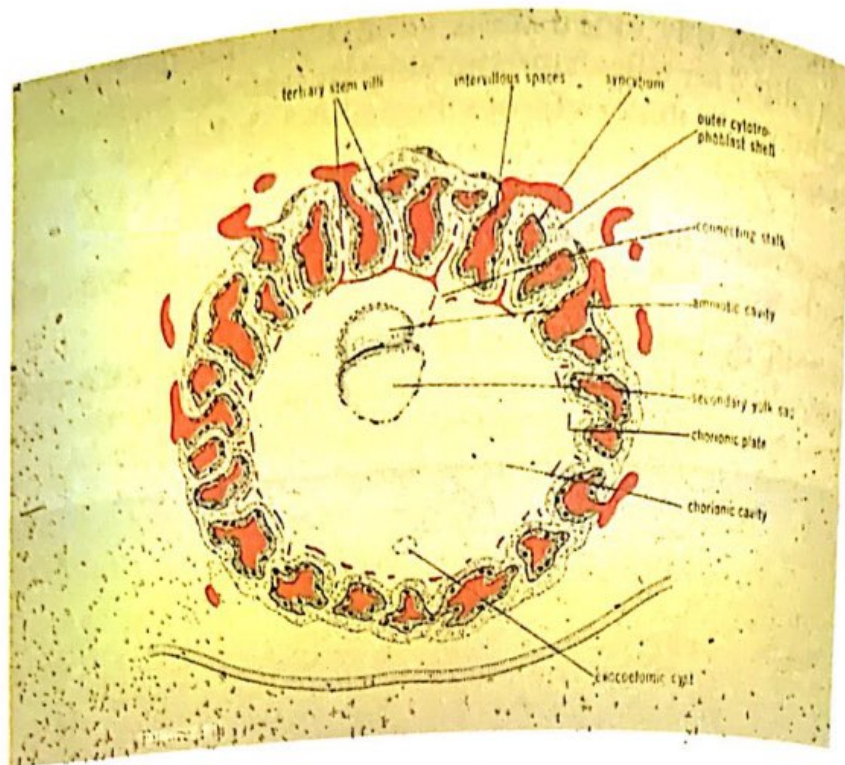



Fig. 88
 Schematic representation of a 3 week embryo. The secondary and tertiary villi completely surrounds the embryo with its amnion and yolk sac. The chorionic membrane form a ball like structure with finger processes arborising from each side.

Those which grow at the side of the mother, i.e. anchoring villi grow markedly and later become part of the placenta, while those away from the attachment to the uterus (womb) atrophy and become known as *Chorion Laevae*.

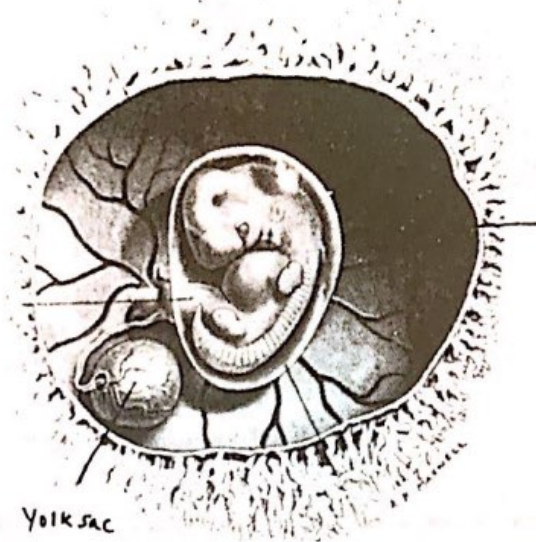
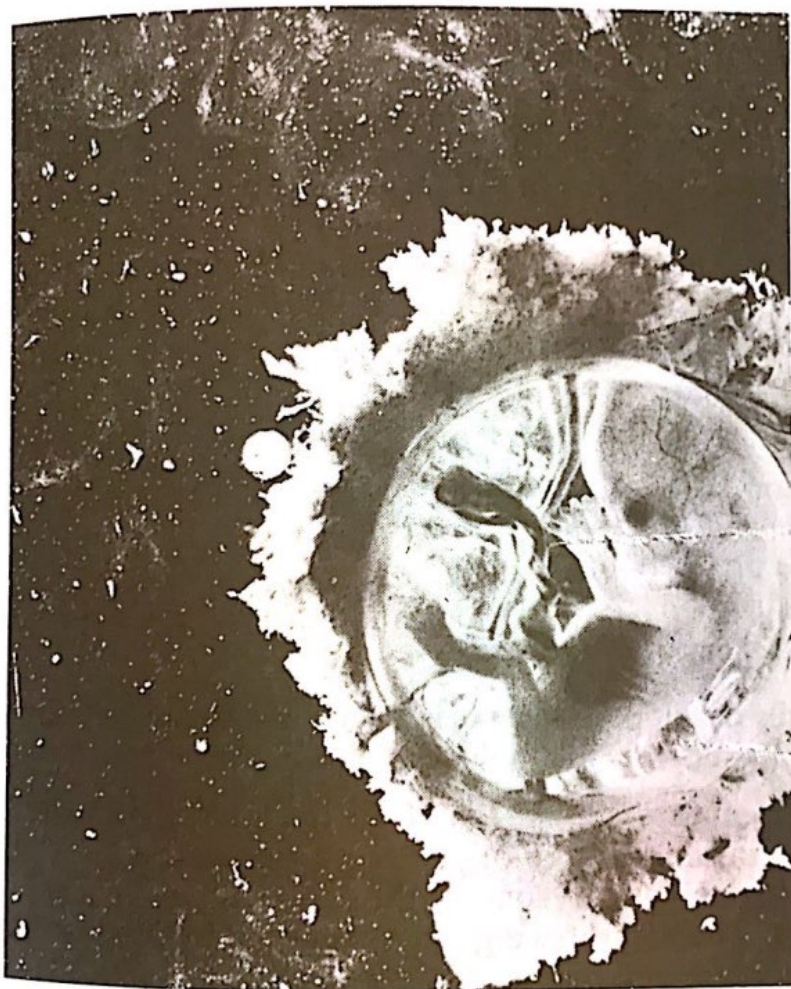
Fig. 89
 The Chorion surrounds the amnion which is slit open to show the embryo and an involuting yolk sac.

*Fig. 90
The chorion is like a ball
from which arborising villi
branch out. It almost resem-
bles a hedgehog covered
with its thorns.*



*Fig. 91
The embryo is suspended in the amnion. The chorion surrounds the*

amnion which are arborising meshy sac that anchors the embryo to the uterus (womb) and supply it with nutrients from the mother. At the same time, it rids the embryo from its waste materials and delivers them to the maternal circulation.

The part of the chorion attached to the mother side (the womb) arborises more and forms, along with the mother's participation, the placenta.

The villi away from the mother side degenerate as the amniotic sac grows, and this side is called Chorion Laevae.

The third Sac is the Decidua. This sac is made by the rest of the endometrium (inner side of the womb) which does not take part in nesting of the blastula. As the embryo grows along with its amnion and chorion, the inner wall of the uterus becomes the third wall. This wall or membrane falls during a parturition (delivery of the baby) and hence given the name decidua i.e. temporary and not permanent.

It is the part that is shed either during menstruation in non-pregnant ladies or which is shed during delivery.

The placenta has two components:

- a) a fetal portion from the chorion
- b) a maternal portion formed by the endometrium

Before birth, the placenta and fetal membranes perform the following functions:

- 1) protection
- 2) nutrition
- 3) respiration
- 4) excretion and
- 5) hormone production.

At birth the fetal membranes and placenta are expelled from the uterus as the afterbirth.

The fully developed placenta is a plate like organ weighing about 500 Gm and containing 100 ml of blood.

The placenta protects the fetus from the injurious and lethal effect of most of the invading micro-organism and chemical substances in the mother's blood. However, some of the micro-organism can pass through the placenta like the viruses e.g. Herpes, the spirochetes of syphilis and the parasites of toxoplasmosis.

The placenta also provide the fetus with maternal antibodies to withstand infection against most micro-organisms.

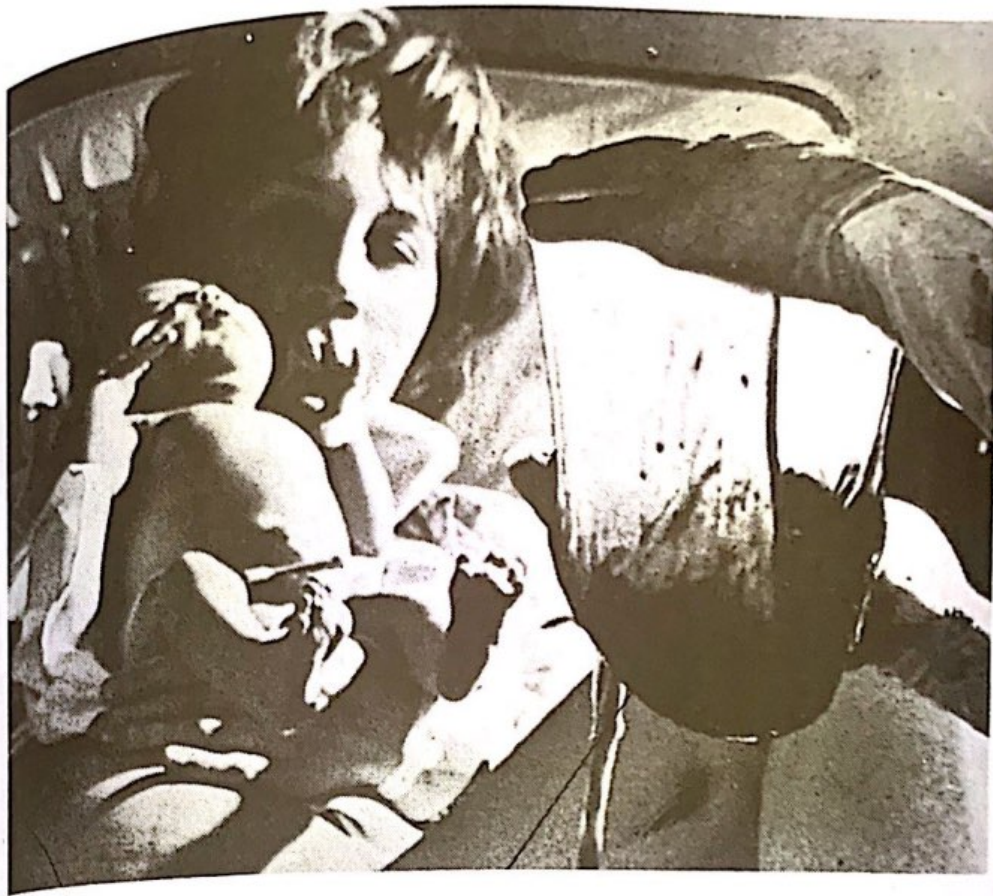

Fig. 92

The placenta held by the obstetrician just few minutes after delivery. The placenta comes out after the delivery of the baby. In obstetrics, it is known to be the third and final stage of labour. It is important to inspect the placenta for any missing parts. Otherwise post partum (after delivery) bleeding or infection may occur.

The obstetrician must remove any remnants out of the womb.

The placenta and membranes, known as afterbirth, were previously discarded and thrown away. Nowadays, hospitals keep them and use them for many a purpose, including grafting of burnt skins, making hormones and even drugs.

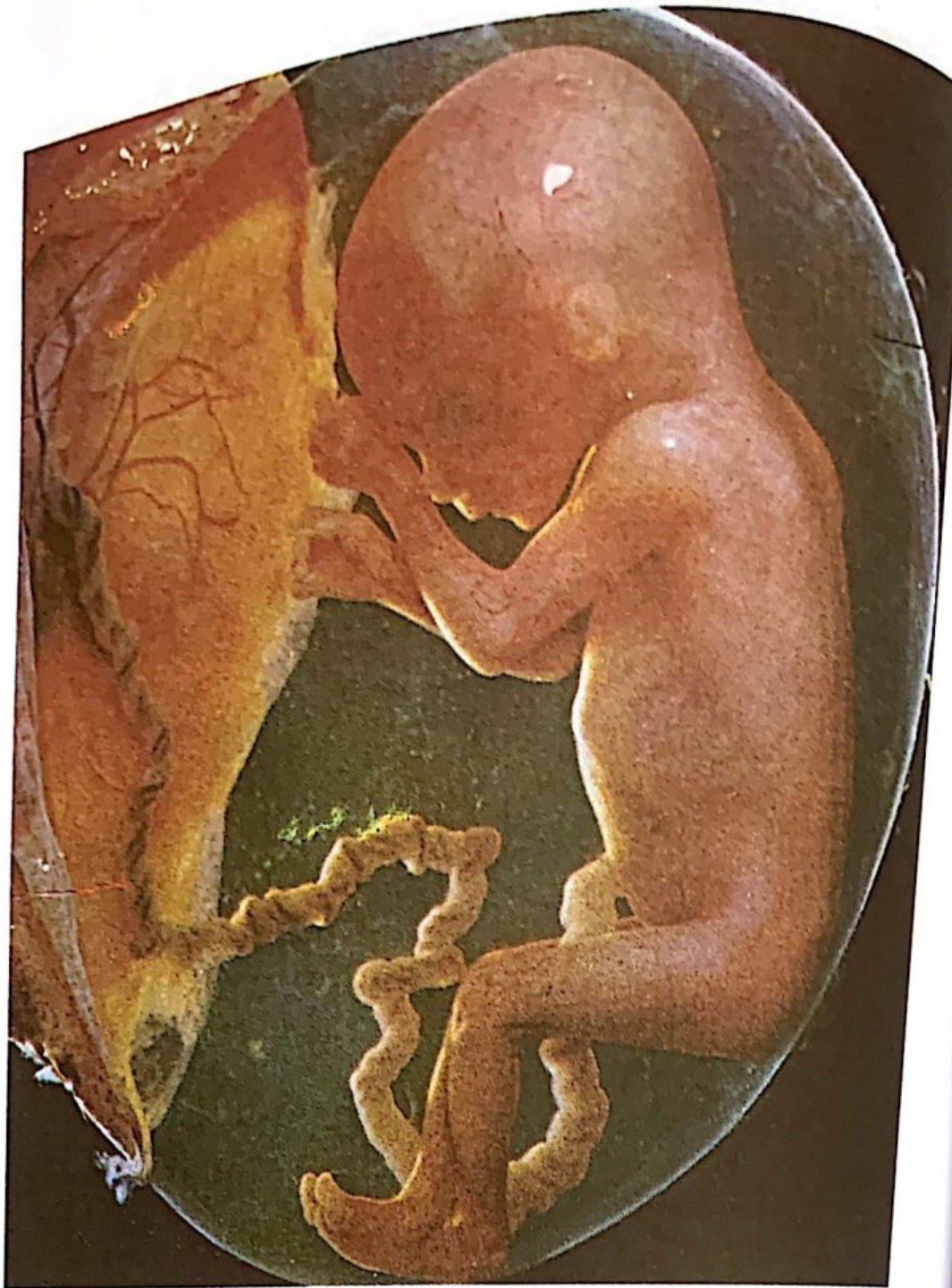
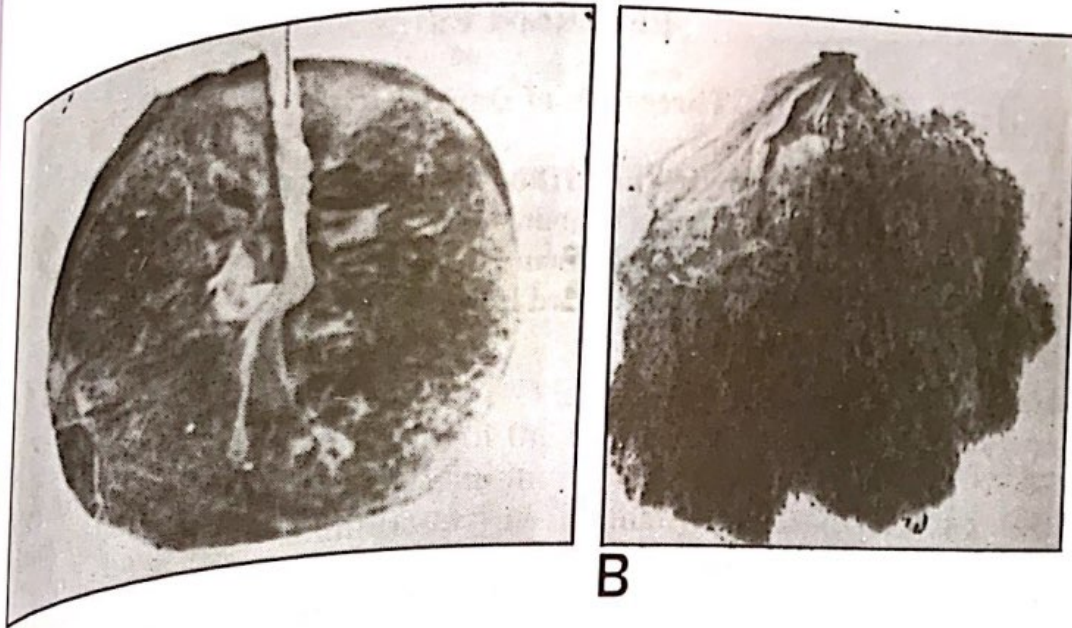


Fig. 93

A fetus 16 weeks old. The placenta is well developed and is attached to the uterine wall. Its fetal surface is covered with amnion and at its centre enters the umbilical cord, which is made of two umbilical arteries conveying CO_2 and waste products from the fetus to be cleared through the placenta, by the mother. It also carries umbilical vein which conveys nutrients, O_2 and antibodies to the growing fetus from the mother via the placenta. No obnoxious or harmful substance is allowed to pass through the placenta to the infant except very rarely. Otherwise, it stands as a sentinel guard, pushing away the intruders and harmful objects.



A

B

Fig. 94

A The placenta fetal side. It is covered by amnion and the umbilical cord attached to its centre.

B The maternal side of the placenta where the anchoring villi, attach the fetus to the mother. It looks like an arborising tree.

These three veils of darkness are very important, for the growth of the embryo and fetus. Exposure to light can hinder the growth and cause malformation.

The Quranic aya (verse) stresses both the evolutionary epigenetic type of creation of the embryo passing from one stage to another, and the importance of these three veils of darkness to procure a normal growth and differentiation of the various tissues of the developing embryo.

Sura 39/6:

“God creates you in the womb of your mothers, one act of creation after another, in three veils of darkness”.

REFERENCES

Three veils of Darkness

- 1) Ibn Kathir (Sura 39/6), Ibn Garir AlTabri, Tafsir AlGalalain etc.
- 2) Keith Moore The Developing Human 3rd Edition (P 126)
- 3) Keith Moore The Developing Human Page 127
- 4) Langman Medical Embryology 3rd Edition Page 103
- 5) Langman P 101, K. Moore. P. 128
- 6) K. Moore P 106
- 7) Langman P 55
- 8) K. Moore P 65

When the soul is inspired?

This is a very difficult subject to tackle. Moslem scholars differed in their definitions and understanding of the soul. However, it is imperative, to discuss here the entry of the soul into the forming fetus. The Quran and Hadith have both mentioned this in many verses (ayas) and many Hadiths. The ulema "the learned of the Muslim nation," for many centuries have discussed it elaborately.

A practical pragmatic issue comes forth by discerning the time of entry of the soul. Many Islamic jurists allow abortion, provided there are medical reasons, before the time the soul enters the body. All of them refute abortion or miscarriage after the entry of the soul to the forming body, except in one situation only, and that is if the life of the mother is endangered. Otherwise, all the jurists refuse to allow abortion after the entry of the soul, even if the fetus is grossly malformed or suffering from congenital or inborn errors of metabolism.

An open neural tube with an anencephaly spina bifida, a hydrocephaly, renal agenesis (absent kidneys) or gross congenital heart abnormalities, whenever diagnosed after the time of the soul entering the body, are no excuse for performing abortion or miscarriage.

This is why it is important to try to study this obscure and difficult subject.

The Holy Quran speaks of "Rooh," soul, in many ayas. At least four meanings were given by the commentators ⁽¹⁾ of the Holy Quran:

- 1) the soul which breathes life into human beings
- 2) the angel Gabriel
- 3) the Quran
- 4) another angel

The first meaning will be discussed here.

The stage at which the soul is breathed into the forming body in the womb occurs after it has passed through the Nutfa, the Alaka, the Mod-

gha, bone formation and flesh formation (that covers the bones stages).

قال تعالى :
« ولقد خلقنا الانسان من سلاله من طين . ثم جعلناه نطفة في قرار مكين ثم
خلقنا النطفة علقه فخلقنا العلقه مضغه فخلقنا المضغه عظاما فكسونا العظام
لحما . ثم أنشأناه خلقا آخر فتبارك الله أحسن الخالقين »

المؤمنون ١٢-١٤

Sura 23/12-14:

“We created man from the quintessence of mud. Thereafter we cause him to remain as a drop of fluid (Nutfa) in a firm lodging (the womb). Thereafter We fashioned the Nutfa into something that clings (Alaka), which We fashioned into a chewed lump (Modgha). The chewed lump is fashioned into bones which are then covered with flesh. Then We nurse him unto another act of creation. Blessed is God, the best of artisans.”

The other act of creation is explained by Ibn Jarir Al Tabri, Ibn Kathir and Al Fakhar Al Razi as being the breathing of the soul unto the forming body.

The Prophet Mohammad (peace be upon him) says:

“The creation of each one of you is collected in forty days: And something that clings (Alaka) he becomes and then a chewed lump (Modgha) for a similar time. The angel is sent to him and the angel writes four things: his provision (sustenance), his age, his deeds and whether he will be wretched or blessed. Then the soul is breathed into him.” Narrated by Moslim Kitab Al Qadar and Al Bokhari (Kitab Al Qadar, Kitab Al Anbiya, Kitab Al Tawhid.)

In another Hadith narrated by Huzaifa Ibn Osaid, the Prophet (peace be upon him) said: “When the Nutfa enters the womb and stays there for forty nights, God sends an angel to give it a form and creates its hearing, sight, skin, bone and flesh. Then the angel asks: O God is it a boy or a girl and God determines whatever He decides. He then asks what is his livelihood and God determines.”

“Narrated by Muslim, Kitab Al Qadar.”

There are many other expressions for the Hadith narrated by Abdulla Ibn Masood quoted by Al Bokhari in Kitab Al Qadar, Al Anbiya, Al Tawhid, and Moslim in Kitab Al Qadar.

Some jurists understood that the Nutfa is 40 days, the Alaka, Modgha are each forty days.⁽²⁾ Others declared that the whole period of formation of Nutfah, Alaka and Modgha is forty days.⁽³⁾

The majority of jurists tend to expand the period to 120 days (17 weeks and one day.)

This may be suitable for the medical profession, as diagnosis of congenital abnormalities or severe inborn errors of metabolism can be diagnosed by amniocentesis at 15th week. Similarly ultra sound studies can be conducted earlier and can detect malformation at an early stage (before 16 weeks).

So long as the foetus has not reached, the hundred and twenty days, it is permissible, in view of most of the jurists, to perform abortion if indicated medically.

However, after the 120th day, abortion is not allowed unless the life of the mother is endangered.⁽⁴⁾ Ibn Hazim⁽⁵⁾ and Zahyria and Sheikh Al Booty are more stringent and even then do not allow miscarriage.

The jurists who claim that the stages of Nutfa, Alaka, Modgha are all collected in forty days, do not specify when the soul is breathed into the forming body. They note that it is definitely after forty days, and after the formation of the organs of the body, including sex organs.

Ibn Al Qaim⁽⁶⁾ puts the following argument:

"If it is asked: Does the embryo before the breathing of the soul unto it, has perception and movement? It is answered that the movement it possesses is like that of a growing plant. Its movements and perceptions are not voluntary. When the soul is breathed unto the body, the movements and perceptions become voluntary and are added to the vegetative type of life it had prior to the breathing of soul."

Ibn Hajar Al Asqalani brings a similar argument when discussing which organs form first. "The liver" he says is the site of nutrition, and growth is needed at that stage, not voluntary movement nor perception. These are acquired when the soul gets attached to the body."

It is quite interesting to find the eminent Ibn Al Qaim and Ibn Hajar Al Asqalani link the soul or spirit being attached to the body, by the appearance of voluntary movements.

It will be remembered from previous chapters (Modgha and bone formation) that somites differentiate into sclerotomes (or forming the bones) and myotomes (forming the muscles), at the fifth week, and in the sixth week the limb buds appear. The muscles of the head, neck and trunk appear by the eighth week, while the perineal muscles appear by the tenth week.

The first voluntary movements appear clearly at the twelfth week.

though it may have started by the eighth week.

The pregnant mother starts feeling the kicking of her unborn child by the 16th week; some mothers a little earlier and some a little later.

That is why the idda (i.e. the period which a widow should abstain from remarrying) is four months and ten days, in order to make sure, whether she is pregnant or not. If she happens to be pregnant, the idda is prolonged until she delivers her baby.

The concept of Ibn Al Qaim and Ibn Hajar Al Asqalani which links the breathing of soul to the appearance of voluntary movements is a remarkable one.

It links human life to volition, and to the integration between muscle and nerve to produce a voluntary action.

The following picture shows fetus sucking his thumb. He is only 4½ months old.




Fig. 95

At 4½ months (18 cm), the fetus rests in the womb covered by the amni-

otic tent sucks his thumb whenever it comes close to his lip, a procedure the infant learns long before he comes out of the womb. He is ready to suck his mother's breasts. God has made his innate reflexes while he is still dwelling in the womb of his mother.

« الذي أعطى كل شيء خلقه ثم هدى » طه ٥٠

Sura 20/50:

“Our Lord is He who gives unto everything (that exists) its true nature and instincts and there upon guides it to perform its function.”

The Nature of the Soul

Nobody knows anything about the nature of the soul.

قال تعالى : « ويسألونك عن الروح . قل الروح من أمر ربي وما أوتيتم من العلم الا قليلا » . الاسراء آية ٨٥

Sura 17/85:

“And they will ask about the soul. Say the soul (cometh) by the Command of my Lord. O Men you have been granted very little knowledge.”

The commentators of the Holy Quran like Ibn Kathir, Ibn Garir, Al Fakher Al Rhazi, Al Baghawi and Al Khazin agreed that the word Rooh here means the soul. The other meaning of “Rooh” like the divine inspiration (the Quran) or the angel Gabriel are not relevant here. However both Yusuf Ali and Mohammed Asad chose the meaning divine inspiration as a translation for the word “Rooh” in this aya (verse.)

The “Rooh” here and the coming Quranic verses mean the soul which gives life to human bodies.

قال تعالى : « فاذا سويته ونفخت فيه من روحي فقعوا له ساجدين »

Sura 38/72:

سورة ص ٧٢

“When I have fashioned him (in due proportion) and breathed into him of My Spirit, fall you down before Him in prostration.”

قال تعالى : « الذي أحسن كل شيء خلقه وبدأ خلق الانسان من طين ثم جعل نسله من سلالة من ماء مهين . ثم سواه ونفخ فيه من روحه . وجعل لكم السمع والابصار والأفئدة قليلا ما تشكرون »

السجدة ٧-٩

Sura 32/7-9:

“He Who makes most excellent everything that He creates. He began the creation of man with (nothing more than) clay, And made his progeny from quintessence of despised fluid. Then He fashioned him in due proportion and then breathed into him something of His Spirit.”

The nature of the soul or spirit, nobody knows of. All that man knows is that when it is breathed in, he gets the human life (after a vegetative life of the Nutfa, Alaka and Modgha,) and when it departs, he is dead.

The signs of human life in the womb do not start at the time of fertilization as many physicians do claim. This is a vegetative life devoid of volition. The human life starts when voluntary muscles contract in the dark environment of the womb and its membranes.

That, as Ibn Al Qaim states, is the beginning of human and not vegetative life.

Other signs may be the writings of the angel on the forehead of the infant. The Prophet (peace be upon him) says: “And the angel writes all that he would face in between his eyes.” (Narrated by Al Bazar).

The lanugo which is found on the forehead of the infant and the finger prints which start during the third month, may be a pointer to this type of undeciphered writing.

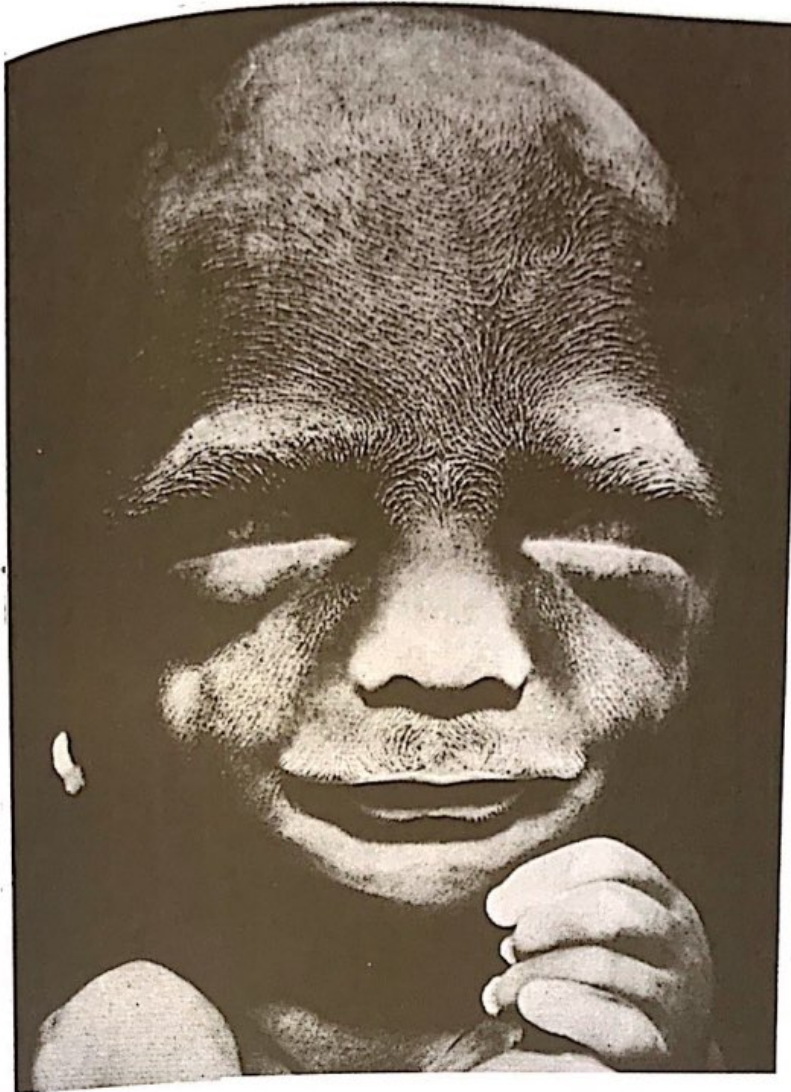


Fig. 96
At 4½ months (25 cm), the lanugo follows the whorl pattern which like the finger prints is highly personal. No two persons are alike. These identity marks are inscribed during the third month of intra uterine life.

The Prophet (peace be upon him) says: "When God creates soul into the body, the angel concerned with the wombs asks: O God! Is it a boy or a girl; and God dictates his Will. The angel then asks is he blessed or wretched, and God dictates. Thereof the angel writes in between his eyes whatever he is going to face in his life." narrated by Ibn Omar (Al Bazar).

An Egyptian idiom says "Whatever is written on the forehead, the eye will witness."

« اللي مكتوب على الجبين لازم تشوفه العين » .

Ibn Hajar Al Asqalani ⁽¹⁾ says, "The writing of the angel occurs twice. It is possible that one is in a sheet and the other on the forehead of the fetus."



Fig. 97

This is a close up of the whorl on the forehead of the fetus at 4¹/₂ months. It has been inscribed during the third month. The Hadith narrated by Ibn Omar (in Al Bazarr textbook of Hadith) proclaims that such inscriptions by the angel occur after the soul has been inspired into the body of the fetus.

It is an identity mark, and a language that still needs to be deciphered.

The Hieroglyphic writings of ancient Egypt were only deciphered when Napoleon invaded Egypt, after discovery of Rosetta stone.

The inscriptions on the forehead will remain to be deciphered one day.

Marks of Identity

During the third month, a highly personal pattern begins to form on the hairless skin of palms and soles, the tips of fingers and toes. The dermis begins to elevate in ridges, with grooves between them. These whorled ridges are different on each individual and will last throughout his or her life. Similar patterns in the skin, all over the body, can be seen in the way the hair grows, although they are not as distinct and individual as the fingerprints.

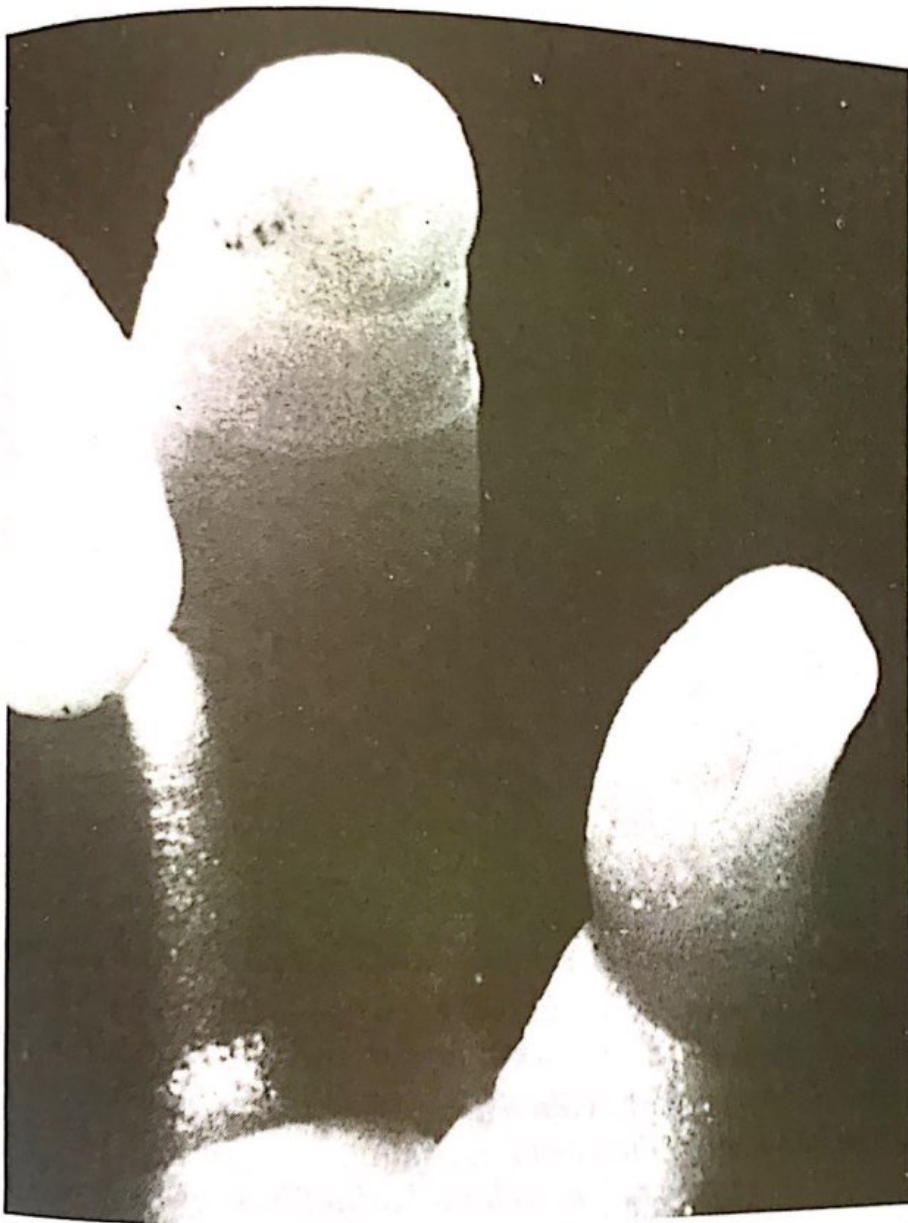

Fig. 98



Fig. 99

The finger prints of each individual are different from any other individual. That is why it is used as the most important mark for identity. There are 4 main types of fingerprints, but each individual has his own pattern within the main groups. These fingerprints are laid down early in uterine life during the third month.

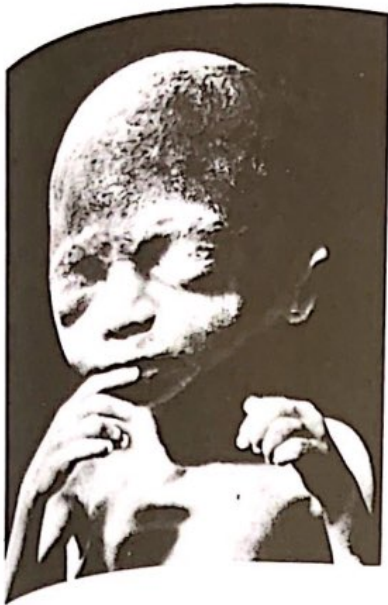


Fig. 100

At 5 $\frac{1}{2}$ months the inscriptions on the forehead are already concealed by a fatty layer called Sebum. The fetus looks as if he is completely absorbed in thinking. Probably he may be considering his fate, which was already inscribed by the angel.




Fig. 101

At 5 $\frac{1}{2}$ months (30 cm long), the fetus makes a lot of movements including grasping the umbilical cord which supplies it via the umbilical vein with O₂ and nourishment, and takes away the obnoxious waste products via the two umbilical arteries.

The Holy Quran and the Prophet (peace be upon him) emphasised the role of the mother and ordered the offspring to pay great respect to the mother, for under her feet the Paradise is found.

REFERENCES

- 1 Ibn Garir Al Tabri
Ibn Kathir
Al Fakher Al Rhazi
Al Baghawi
Al Khazin
Al Qurtubi
Al Galalain
Surat Al Isra 17/Verse 85
- 2 Al Nawawi, Shareh Sahih Moslem Kitab Al Qadar
- 3 *Ibn Hajar Al Asqalani*: Fateh Albari Shareh Sahih Al Bokhary, Kitab Al Qadar, Vol II, Page 481
- 4 *Ibn Al Qaim* Atibian Fi Aqşam Al Quran, and quoted by Ibn Hajar in Fateh Albari
- 5 *Ibn Abdeen* Hashya Vol 1/310
- 6 Fatawa Shaloot and Al Qardawi, Al Halal Wal Haram P 194
- 7 Ibn Hazim, Al Mohala Vol II/P. 31;
- 8 Sheikh M.S. R. Al Booty, Masalat Tahdid Annasel P 100 — 107
- 9 Ibn Al Qaim, Al Tibian Fi Aqşam Al Quran P 255
- 10 Ibn Hajar, Fateh AlBary, Kitab Al Qadar Vol II/482

References Arabic Books

The Holy Quran, its Translations and Tafsir

- 1 The Holy Quran
- 2 Muhammad Asad: The Message of the Quran, Dar Al Andalus, Gibraltar
- 3 Yusuf Ali: Translation of the Holy Quran, Qatar National Printing Press
- 4 Ibn Garir Al Tabari: Gami Al Bayan Fi Tafsir Al Quran, Dar Al Marifa, Beirut
- 5 Ibn Kathir Al Dimashqy: Tafsir Al Quran Al Azim, Dar Ihya Al Kotab Al Arabia, Cairo
- 6 Al Qurtubi: Al Gama Lihakum Al Quran
- 7 Al Baghawi: Maalem Al Tanzil, Dar Al Fiker
- 8 Al Ghazin: Lubab At Tawil Fi Maani Al Tanzil, Dar Al Fikr
- 9 Al Oolosi
- 10 Al Fakher Al Rhazi: Al Tafsir Al Kabir, Dar Al Kotob Al Ilmiah, Tehran
- 11 Al Maraghi
- 12 Syed Qotob: Fi Dilal Al Quran, Sixth Edition
- 13 Ibn Albooz: Zad Al Maseer Fi Ilm Atfsir
- 14 Ibn Al Qaim: Al Tibian Fi Aqam Al Quran
- 15 Al Galalin: Tafsir Al Galalaim, Al Maktaba Asshabia

Hadith

- 1] Al Bokhari: Sahih Al Bokhari: Arabic and English translation by
- 2] Moslim: Sahih Moslim
- 3] Ibn Hajar Al Asqalan: Fateh Al Bary Shareh Sahih Al Bokhari
- 4] Al Nawawi: Shareh Sahih Moslim
- 5] Mohammed bin Mohammed bin Suliman: Gama Al Fawaid

Dictionaries

- 1] Dr Abdulla Abbas Al Nadwi: Vocabulary of the Holy Quran, Dar Asshoroq, Jeddah
- 2] Mohammad Fouad Abdul Bagi: Al Mo Goam Al Mophahraes, Kitab Al Shaab, Cairo
- 3] Al Johari: Al Sihah, Iahqiq Al Attar, 2nd Edition
- 4] L. Maloof: Al Monjid, 19th Edition, Catholic Press, Beirut

English Books

1. Arey, Leslie: Developmental Anatomy, 7th Edition, Saunders Company 1974
2. Hamilton, Boyd, Mossman: Human Embryology, 4th Edition, Macmillan Press, London 1976
3. Langman, Jan: Medical Embryology, 3rd Edition, Williams & Wilkins, 1975 Baltimore, U.S.A.
4. Moore, Keith: The Developing Human, Saunders Company, 3rd Edition 1982
5. Nilsson, Lennart: A child is Born, Faber & Faber, London 1977
6. Medicine Digest: June 1981
7. Hamilton W.J. Textbook of Human Anatomy, 2nd Edition, 1976 Macmillan Press Ltd, London.